

SPECT and PET (CT) Imaging in Vascular Graft Infection

Olivier Gheysens, M.D., Ph.D.¹
Christophe Van de Wiele, M.D., Ph.D.²

Departments of Nuclear Medicine
University Hospitals Leuven, Belgium¹
University Hospital Ghent, Belgium²

SUMMARY

- VGI: descriptives, causes, risk factors
- Clinical presentation
- Diagnosis
 - Morphological imaging
 - Functional imaging
 - SPECT/CT
 - PET/CT
- Conclusions

Vascular Graft Infection (VGI)

- Incidence: 0.5-5% , severe complication
 - Infra-inguinal 2-5%
 - Aortofemoral 1-2%
 - Aortic grafts 1%
- ≥ 4 months following surgery
- Early, accurate diagnosis: challenging and of utmost clinical significance for further management
- Delay in treatment : severe complications, e.g. sepsis, haemorrhage, amputation
- Main successful therapeutic option: surgery for removal of infected graft - major procedure with high morbidity (eradication is rarely possible after graft is infected)
- Poor prognosis: related to anatomical site (aortic), may result in life or limb loss (>50% of patients)

Causes of VGI

- faulty sterile surgical technique
- long preoperative hospitalization (hospital-acquired strains)
- extended operative time / emergency procedures
- postop. wound infection, skin necrosis, hematoma, seroma, lymphorrhea – graft thrombosis and infection
- remote infection site - hematogenous or lymphatic spread
- reintervention (mainly at < 30 days) - higher incidence of graft infection

Risk factors for VGI

- Groin incision
- Wound complications
- Immunosuppressive therapy
- Diabetes
- Cancer
- Immunologic disorders

SUMMARY

- VGI: descriptives, causes, risk factors
- **Clinical presentation**
- Diagnosis
 - Morphological imaging
 - Functional imaging
 - SPECT/CT
 - PET/CT
- Conclusions

Clinical Presentation of VGI

- Mild or fulminant (anatomic location & pathogen virulence)
- more common: inguinal region (aorto-bi-fem, fem-popliteal)
- common pathogens
 - Staph (25-50%),
 - S aureus (early)
 - Coagulase – S (late)
 - recent increase in the MRSA (up to 20%, early)
 - +/- 25% polymicrobial
- presentation: local pain, redness, lump and/or secretion in the surgical wound.
- lab exam: moderate rise in WBC & ESR
- infected abdominal/thoracic grafts: more indolent course & more difficult diagnosis

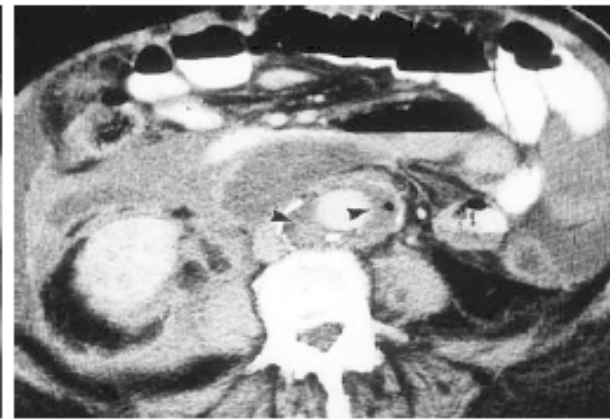
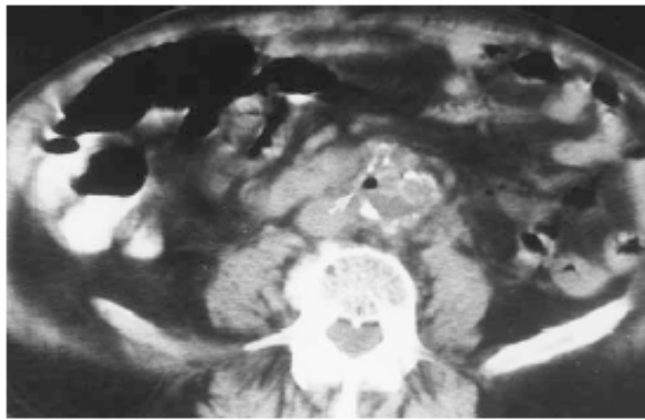
SUMMARY

- VGI: descriptives, causes, risk factors
- Clinical presentation
- **Diagnosis**
 - Morphological imaging
 - Functional imaging
 - SPECT/CT
 - PET/CT
- Conclusions

Diagnosis of VGI

CT

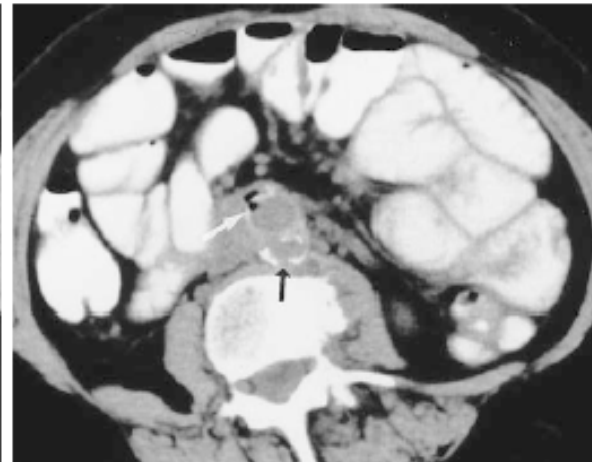
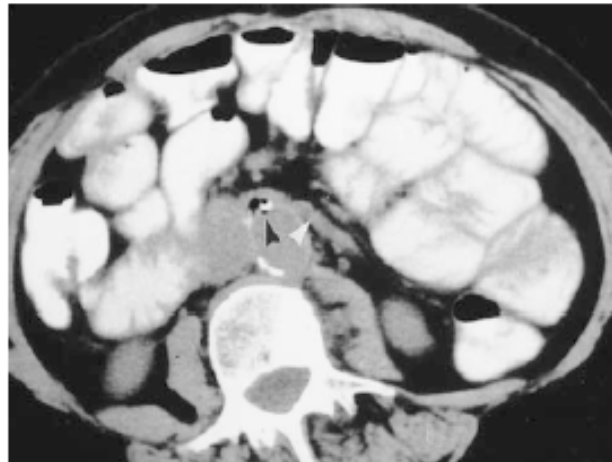- True Gold standard: culturing
- Imaging Gold standard = HRCT (MRI?) (Se 94% (50% if low grade)/Sp: 85%) (1)
 - Imaging criteria (time-related):
 - Perigraft fluid
 - Perigradt soft-tissue attenuation
 - Ectopic gas
 - Pseudo-aneurysm
 - Focal bowel wall thickening
 - False positive:
 - bubbles – normal CT pattern up to 6 weeks after surgery
 - perigraft infected vs. sterile fluid
 - False negative:
 - low-grade infection
 - early stages (insignificant/no structural alterations)



1.

2.

Figures 1, 2. (1) Normal findings in a patient with abdominal pain 1 week after elective aneurysm repair. CT scan shows air around the aortic graft (arrow). The abdominal pain subsided, with an otherwise uneventful postoperative course. (2) Normal findings in an 87-year-old woman with spiking fevers 1 week after repair of a ruptured aortic aneurysm. CT scan shows perigraft fluid and air (arrowheads), which are within normal limits for this early postoperative period. The ascites was transudative, and the culture was negative. The fevers were due to a lung abscess (not shown).



4a.

4b.

Figures 3, 4. (3) Perigraft air secondary to graft infection in an asymptomatic patient. The patient originally presented with anemia and a hemoglobin level of 7 g/dL (70 g/L). Because of the possibility of an aortoenteric fistula (the patient had a history of duodenal ulcer), endoscopy was performed but showed no evidence of an aortoenteric fistula. (a) CT scan shows perigraft air (arrowhead), which was an incidental finding. Because the patient had undergone surgery nearly 2 years earlier, the diagnosis of graft infection was almost certain; however, owing to the lack of symptoms, a gallium scan was obtained. (b) Gallium scan shows increased uptake at the mid-abdominal aorta (arrows), thus confirming the diagnosis of infection. Cultures of the graft showed growth of *Citrobacter diversus*.

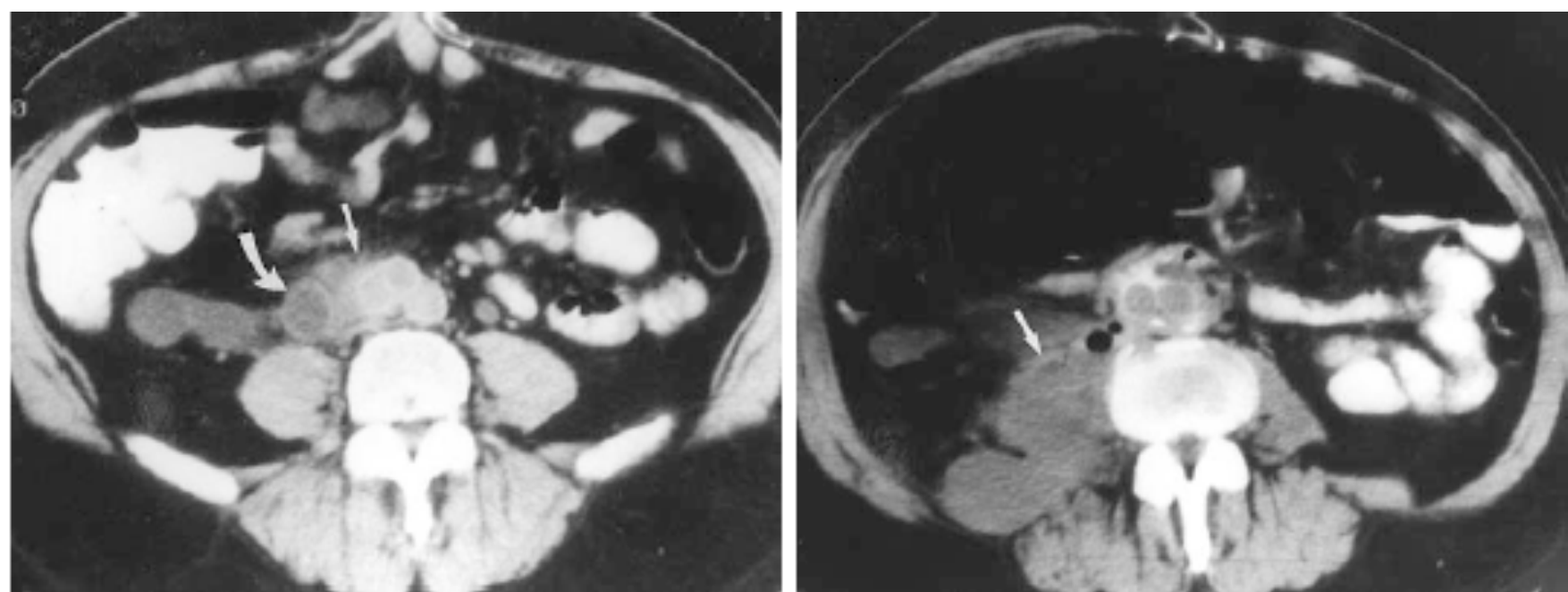
(4) Aortoenteric fistula in a patient with new-onset heme-positive stools and a history of aortic repair. (a) CT scan shows gas near the beginning of the graft (black arrowhead). The duodenum is closely adjacent (white arrowhead). (b) Contiguous CT scan obtained inferior to a shows perigraft air (white arrow) and the collapsed native aortic bed posterior to it (black arrow). Cultures of the graft were negative.

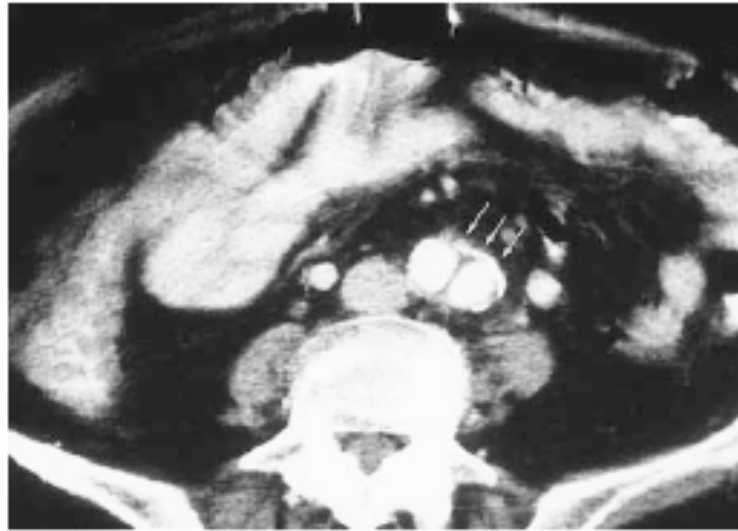

Figure 5. Normal perigraft ring. CT scan shows perigraft tissues that are no more than 5 mm thick (arrows).

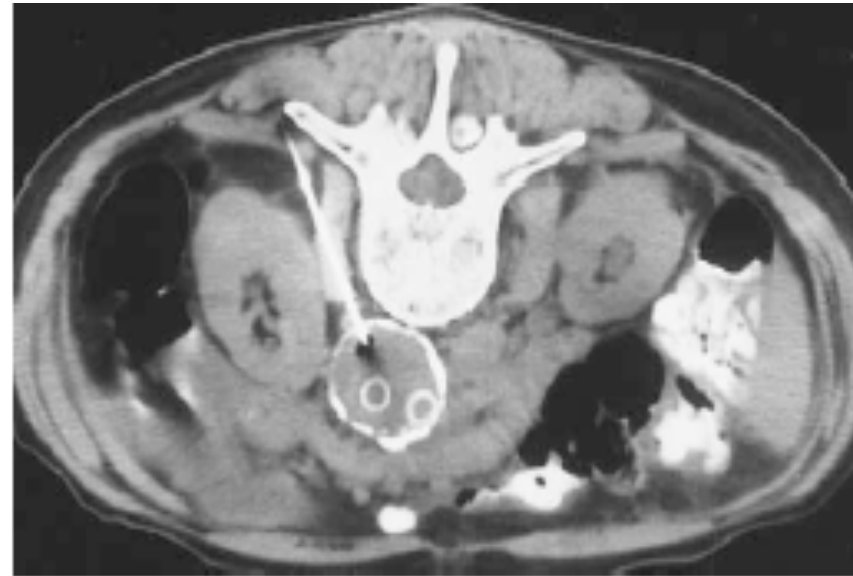

Figure 7. Perigraft fluid collection in the left groin in a patient with persistent fever and elevated WBC count 4 months after surgery. CT demonstrated a persistent fluid collection around the graft. Because an infection could not be ruled out, CT-guided aspiration was performed. CT scan shows aspiration of the fluid collection, which demonstrated no bacterial growth but abundant WBCs. The fluid collection eventually showed growth of *Campylobacter fetus*. The patient and surgeon opted for treatment with antibiotics and close follow-up, which proved successful in the long term.



a.

b.

Figure 9. Graft infection in a patient with an aortic bifurcation graft. (a) CT scan obtained several years after graft placement shows that the wall of the right limb of the graft is indistinct (straight arrow), merging with an area of soft-tissue attenuation and without a circular rim of fat. This appearance was not recognized at the time as a very suspicious finding for graft infection. A fluid-filled loop of ileum is present anterior to the right psoas muscle (curved arrow). The abnormality was not recognized until development of an obvious graft infection and psoas abscess 1 year later. (b) CT scan obtained approximately 1 year later shows a right psoas abscess in the same location, contiguous with the graft (arrow) (window width and level were changed to show the abscess better). At surgery, there was staining of the graft in this location, indicating an enteric fistula.

SUMMARY

- VGI: descriptives, causes, risk factors
- Clinical presentation
- **Diagnosis**
 - Morphological imaging
 - **Functional imaging**
 - SPECT/CT
 - PET/CT
- Conclusions

Diagnosis of VGI

Functional Imaging modalities

- SPECT :
 - ^{67}Ga scan - limited value , relatively low sensitivity
 - Labeled WBCs: (Se 53-100%/Sp50-100%) (1)
 - FP: perigraft haematoma, thrombosed grafts/bleeding/recent surgery
 - Other: Human Immunoglobulin, Antigranulocyte Ab (Tc-Fanolesomab), Peptides
- PET :
 - FDG (Fluorodeoxy-Glucose) (PET) (91%Se/64%Spe, Fukuchi et al.)

: early 2000'

Functional & Metabolic Imaging VGI

Pros:

- High sensitivity: diagnosis in early phases (no anatomic lesion detectable yet)

Cons:

- Poor physical characteristics (image quality degradation)
- Lack of anatomical landmarks
- Non-specificity of tracers

Added Value of Hybrid Imaging in Assessment of Vascular Graft Infection

- Side-by-side SPECT/PET & CT comparison - difficult:
 - Closer proximity of structures (in limbs)
 - Mis-registration in cases of minimal positional changes (which may occur involuntary)
- SPECT/CT & PET/CT:
 - facilitates image interpretation & clinical decision making
 - Better definition of tracer uptake: exclude or confirm the presence of infection (SPECT/PET)
 - Correct anatomical localization of the identified focus (soft tissue/graft via CT)
 - Improves therapy planning, antibiotics

SUMMARY

- VGI: descriptives, causes, risk factors
- Clinical presentation
- **Diagnosis**
 - Morphological imaging
 - Functional imaging
 - **SPECT/CT**
 - PET/CT
- Conclusions

Ga-67 & WBC SPECT/CT for Diagnosis and Localization of Infection

Bar-Shalom et al, J Nucl Med 2006

82 patients

SPECT/CT – better diagnosis & localization in ~50% pts

Ga-67 SPECT/CT contributory in 36% of 47 pts

48% with susp. osteomyelitis

23% with susp. soft-tissue infection

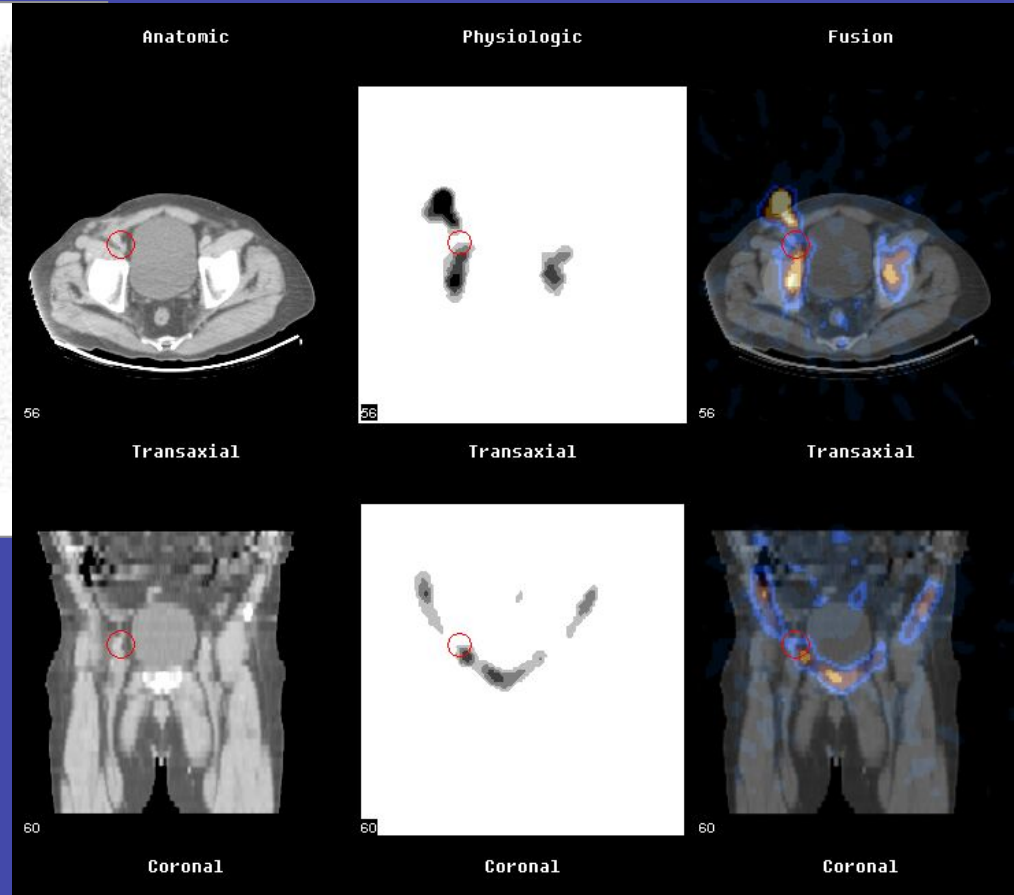
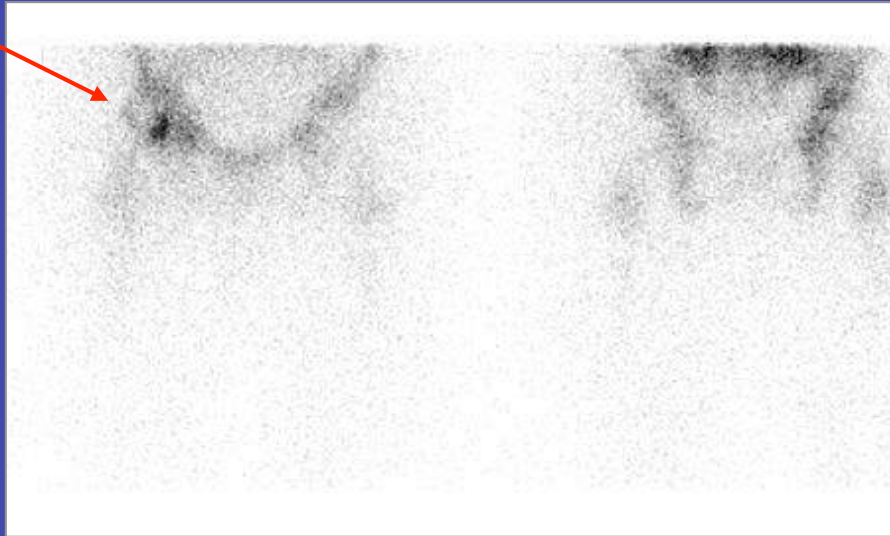
31% with FUO

WBC - SPECT/CT was contributory in 63% of 35 pts:

67% - with susp. vascular graft infection

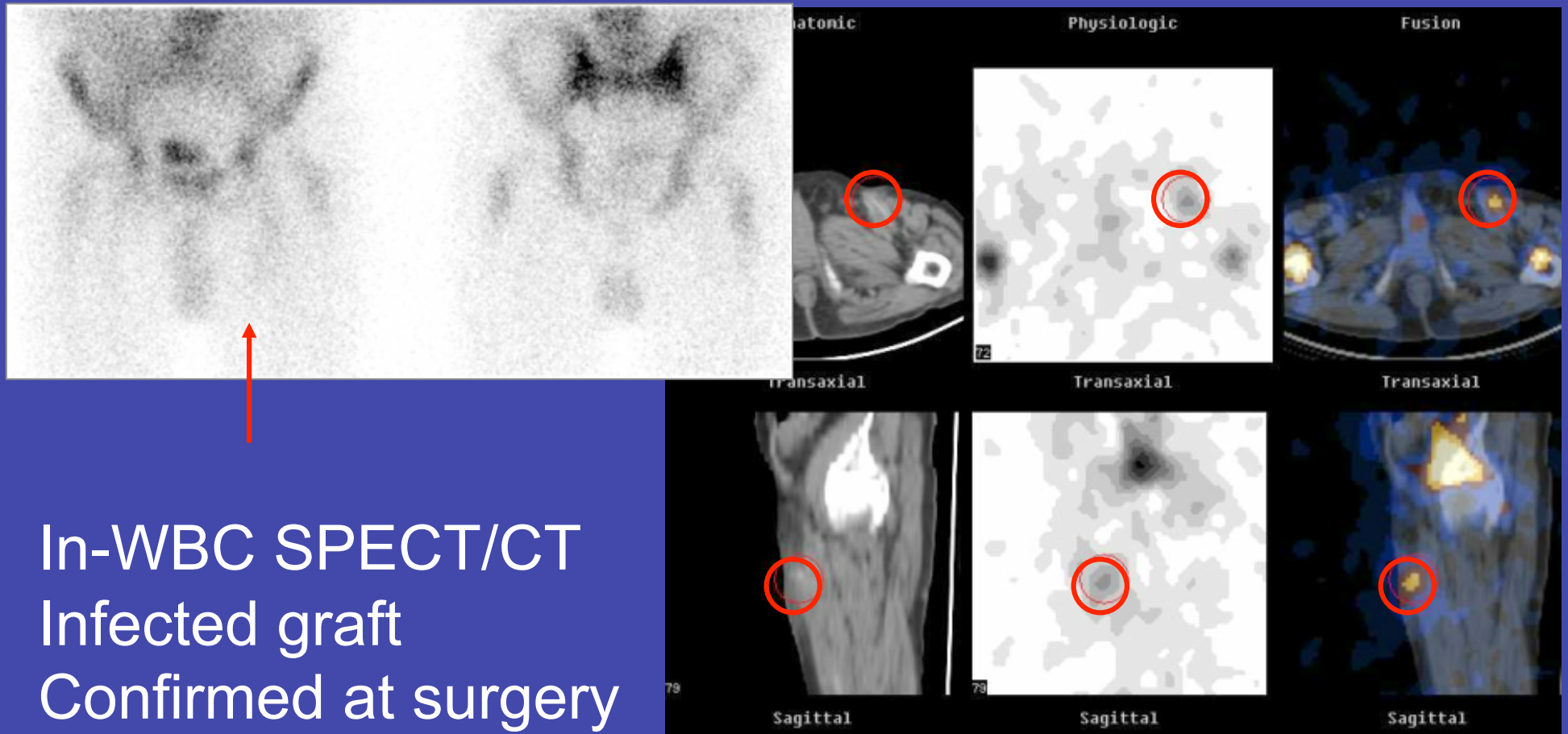
55% - with susp. osteomyelitis

M, 59, S/a aorto-bifem bypass,
pus secreting wound in rt. groin



In-WBC SPECT/CT
Infected wound
No graft involvement
Conservative Rx & complete resolution

M, 57, S/a Rt. fem-pop bypass
Fever, Leucocytosis, Infected surgical wound



SUMMARY

- VGI: descriptives, causes, risk factors
- Clinical presentation
- **Diagnosis**
 - Morphological imaging
 - Functional imaging
 - SPECT/CT
 - **PET/CT**
 - **Clinical data**
 - Interpretation: pitfalls
 - Challenging situations
- Conclusions

TABLE 1
Summary of Published Studies Using ¹⁸F-FDG in Vascular Graft Infection

Study	Year	No. of patients	Method*	¹⁸ F-FDG dose [†] (MBq)	Acquisition time [‡] (minutes after injection)	Interpretation criteria [§]	True-positive	True-negative	False-positive	False-negative
Stumpe (7)	2000	7	PET	300–400	30–40	Qualitative	2	5	0	0
Krupnick (12)	2003	1	PET	187	50	Qualitative	1	0	0	0
Chacko (8)	2003	3	PET	2.55/kg	60	Qualitative	2	1	0	0
Keidar (11)	2003	1	PET/CT	370	60	Qualitative	1	0	0	0
Städler (14)	2004	1	PET/CT	375	90	Qualitative	1	0	0	0
Fukuchi (15)	2005	33	PET	185	60	Semiquantitative	10	14	8	1
Jaruskova (9)	2006	7	PET/CT	279–717	40–165 (mean, 70)	Qualitative	6	0	1	0
Tsunekawa (16)	2007	1	PET	185	60	Qualitative	1	0	0	0
Tegler (25)	2007	1	PET/CT	—	—	Qualitative	1	0	0	0
Keidar (29)	2007	39	PET/CT	185–370	90	Qualitative based on morphology	14	22	2	1

*Shows morphologic accuracy in detecting site of ¹⁸F-FDG uptake.

[†]¹⁸F-FDG dose is usually related to image acquisition time.

[‡]Early or delayed imaging may lead to different diagnostic accuracy.

[§]Qualitative or quantitative interpretation may also depend on method used.

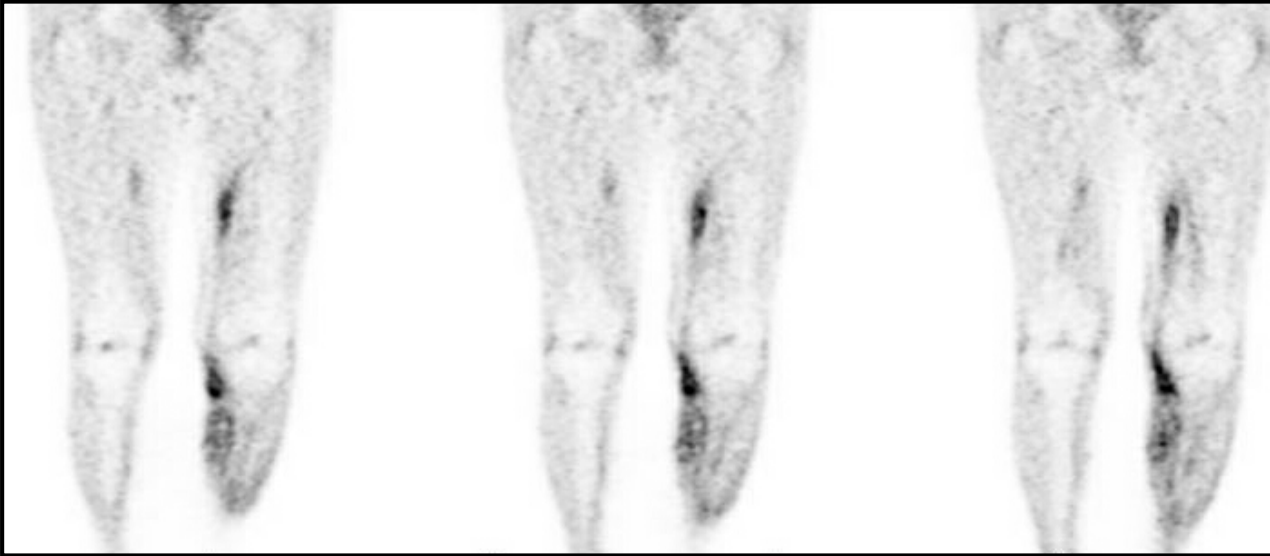FDG PET(-CT) IMAGING IN ENDOVASCULAR GRAFT INFECTION

Detection of aortic graft infection by FDG PET: comparison with computed tomographic findings

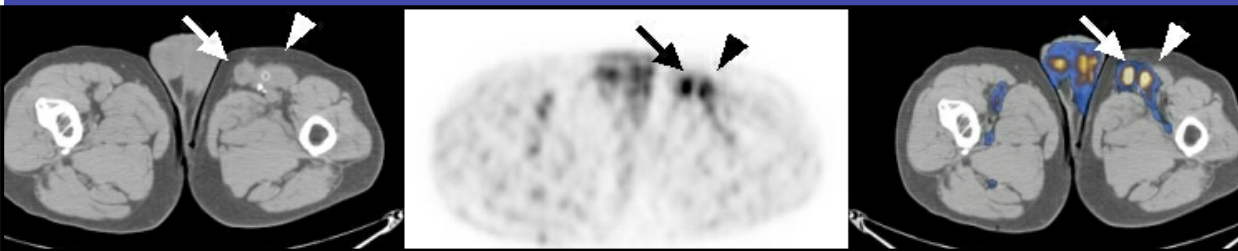
- N = 33 pts, clinical suspected arterial prosthetic graft infection
- Gold standard: surgical, microbiological and clinical FU findings

	Sensitivity	Specificity
CT	64%	86%
PET	91%	64% If only focal uptake was considered, up to 95% !

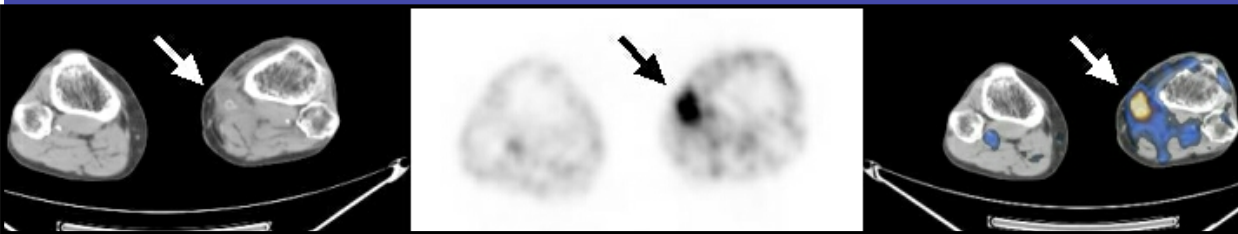
M, 74, s/a lt. fem-posterior tibial bypass



FDG+ foci – along medial aspect of lt. lower limb



Upper thighs - infected graft & soft tissue abscess



At knee level - infected graft

FDG PET(-CT) IMAGING IN ENDOVASCULAR GRAFT INFECTION

Prosthetic vascular graft infection: the role of 18F-FDG PET/CT

- N = 39 pts, prospectively, unenhanced CT
- Total of 69 grafts (femoropop, aortobifem, other) of which 40 were clinical suspected for infection of prosthetic vascular graft
- FDG PET uptake criteria:
 - no or only linear uptake of low to moderate intensity along the graft region: considered negative
- Correlation with histopathology or clinical follow-up

FDG PET(-CT) IMAGING IN ENDOVASCULAR GRAFT INFECTION

Prosthetic vascular graft infection: the role of 18F-FDG PET/CT: results :

	Sensi	Specif	PPV	NPV
PET/CT	93%	91%	88%	96%

- No uptake in any of the 29 not clinically suspected graft
- Co-registration with CT helps to determine location of the focus: graft or surrounding tissue

FDG PET(-CT) IMAGING IN ENDOVASCULAR GRAFT INFECTION

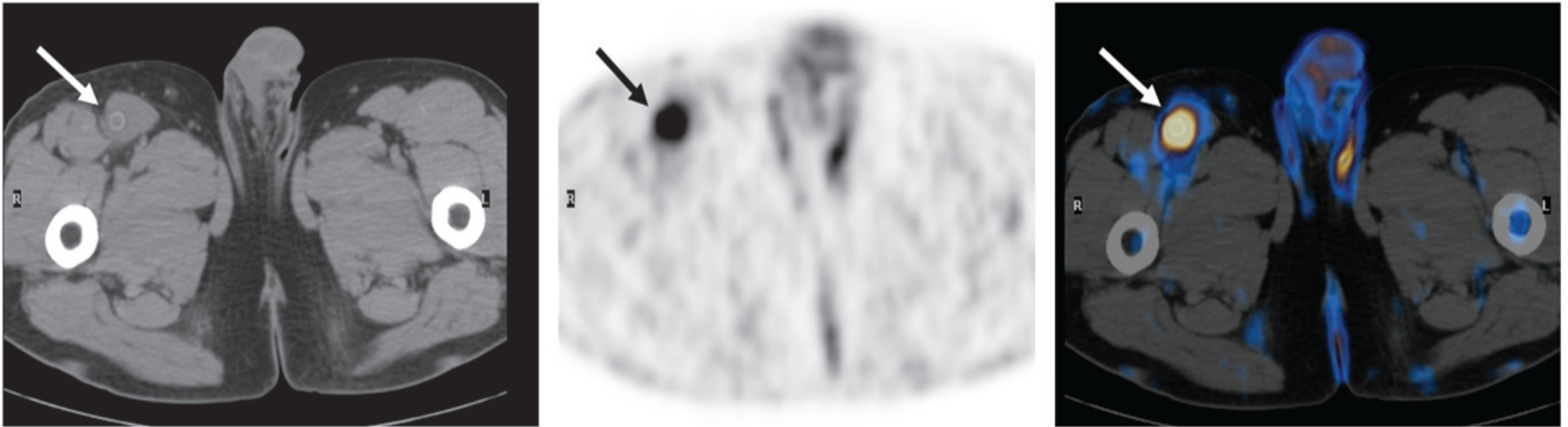


FIGURE 1. A 54-y-old man who had received right femoropopliteal bypass graft 3 mo previously. Infection was clinically suspected because of fever and local pain in right groin. ^{18}F -FDG PET (center) demonstrates focus of increased tracer uptake in right groin (arrow), localized by PET/CT (right) to right femoropopliteal vascular graft as seen on CT (left, arrow). Graft was considered to be involved by infectious process. Diagnosis was confirmed at surgery, and infected graft was removed.

Keidar et al, J Nucl Med Aug 2007;48:1230-1236

FDG PET(-CT) IMAGING IN ENDOVASCULAR GRAFT INFECTION

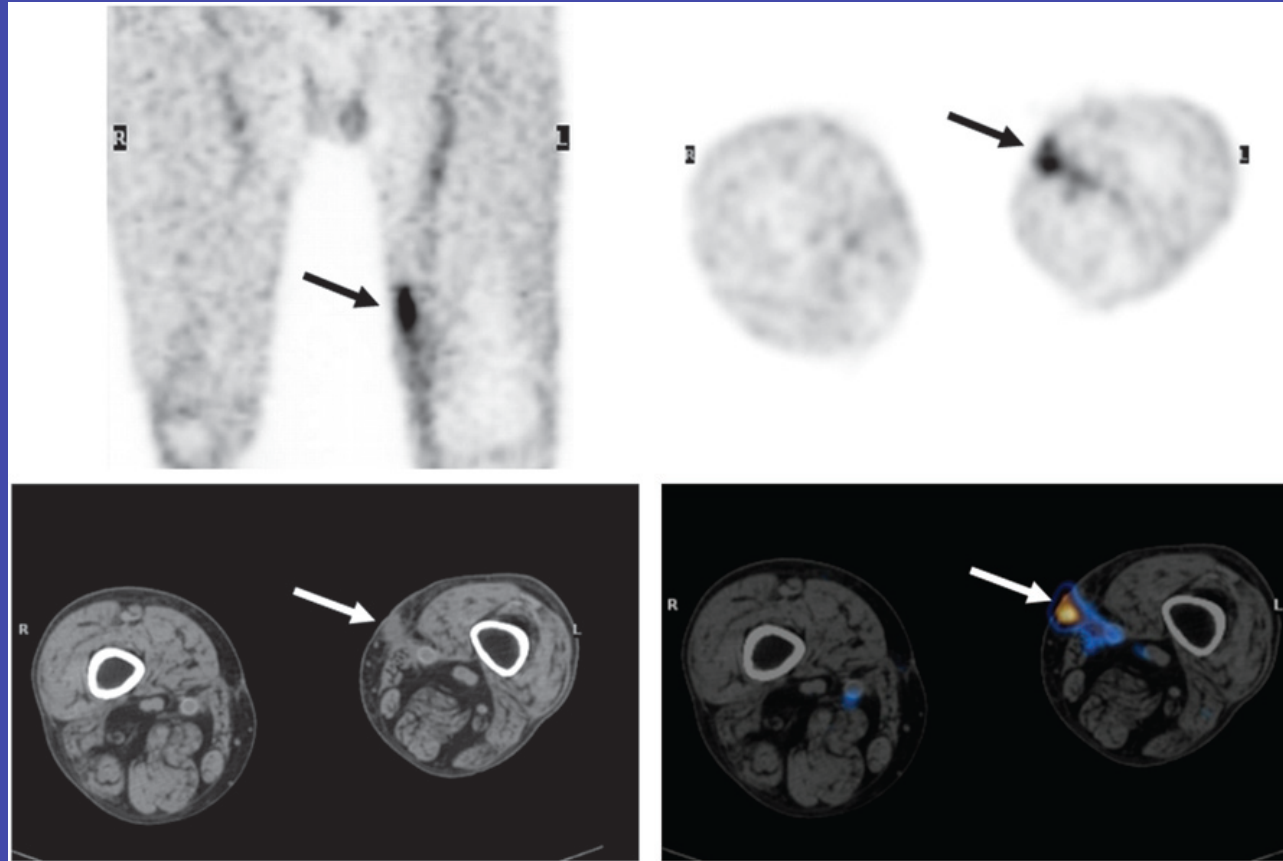


FIGURE 2. A 68-y-old man who had received left femoropopliteal bypass graft 18 mo previously. Infection was clinically suspected because of fever and infected surgical wound in medial aspect of left distal thigh. Coronal (top left) and transaxial (top right) ^{18}F -FDG PET images show area of increased uptake in (arrows), localized by PET/CT image (bottom right) to soft tissue swelling (arrow) adjacent to left femoropopliteal graft as seen on CT (bottom left). Patient responded rapidly to antibiotic therapy, and no vascular graft infection was evident on long-term follow-up of 14 mo.

SUMMARY

- VGI: descriptives, causes, risk factors
- Clinical presentation
- **Diagnosis**
 - Morphological imaging
 - Functional imaging
 - SPECT/CT
 - **PET/CT**
 - Clinical data
 - **Interpretation: pitfalls**
 - Challenging situations
- Conclusions

PET/CT Ability to Characterize FDG-avid Processes Unrelated to Graft Infection (previously false positive)

- Venous thrombosis
- Sterile inflammation
- Foreign body or surgery-related inflammatory reaction
- Retroperitoneal fibrosis (abdominal grafts)
- Vasculitis

FDG - PET/CT

Evaluation of Infected Vascular Graft

Pitfalls & Limitations

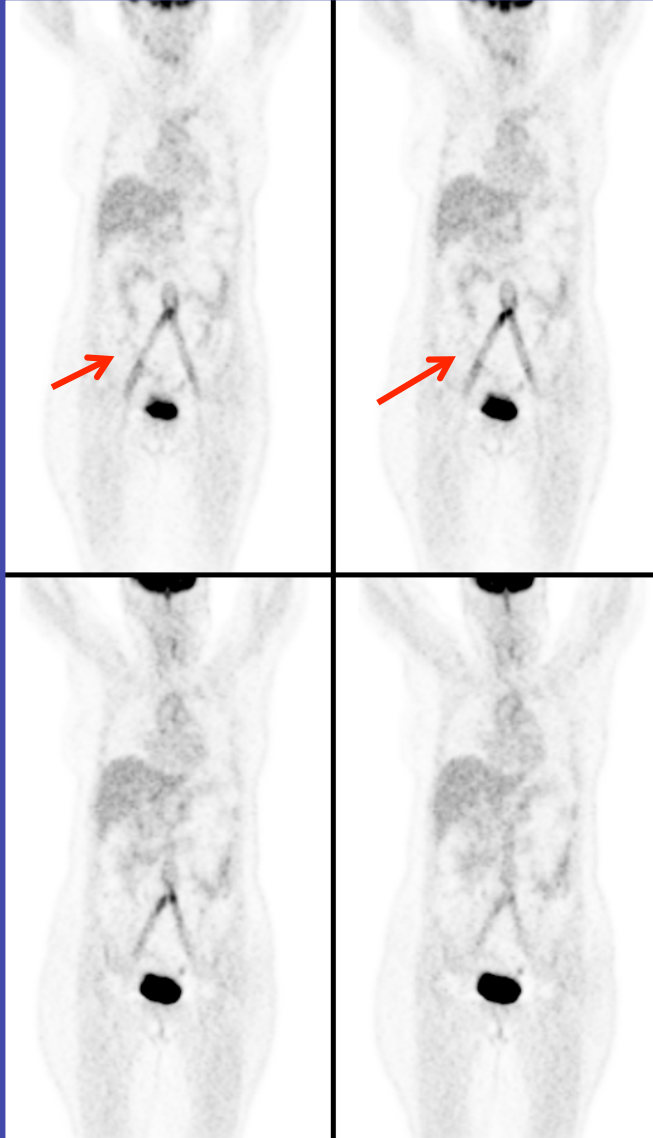
- non-infected grafts: mild, linear, diffuse FDG uptake - ? low grade foreign body-related inflammatory reaction
- FDG+ in post-surgical inflammation, scar & native vessels
- FDG+ foci of adjacent soft tissue infection

non-infected grafts - foreign body inflammatory reaction

Wasselius et al, JNM 2008

- 16 pts, synthetic aortic grafts (retrospective among 2,045 pts)
- High FDG uptake
 - 10/12 grafts after open surgery
 - 1/4 grafts after endovascular repair
- Retrospective potential infection: 1/16 pts
- “FDG uptake in vascular grafts *in vast majority* of patients without graft infection. *The risk* of a false-positive diagnosis by FDG-PET/CT *is evident*”

FDG Avidity in Non-Infected Vascular Graft



F, 56 , NSCLC

s/a aorto-bifemoral - 12 years

Pattern:

- Diffuse, linear, moderate intensity
- Frequent in recent implants
- Can persist for years after surgery.

Hypothesis:

Chronic aseptic inflammatory process related to the synthetic graft material, mediated by macrophages, fibroblasts, and giant cells.

FDG & CT Patterns Differentiating Infected vs. Non-Infected Prosthetic Vascular Grafts

Spacek et al, EJNMMI 2008

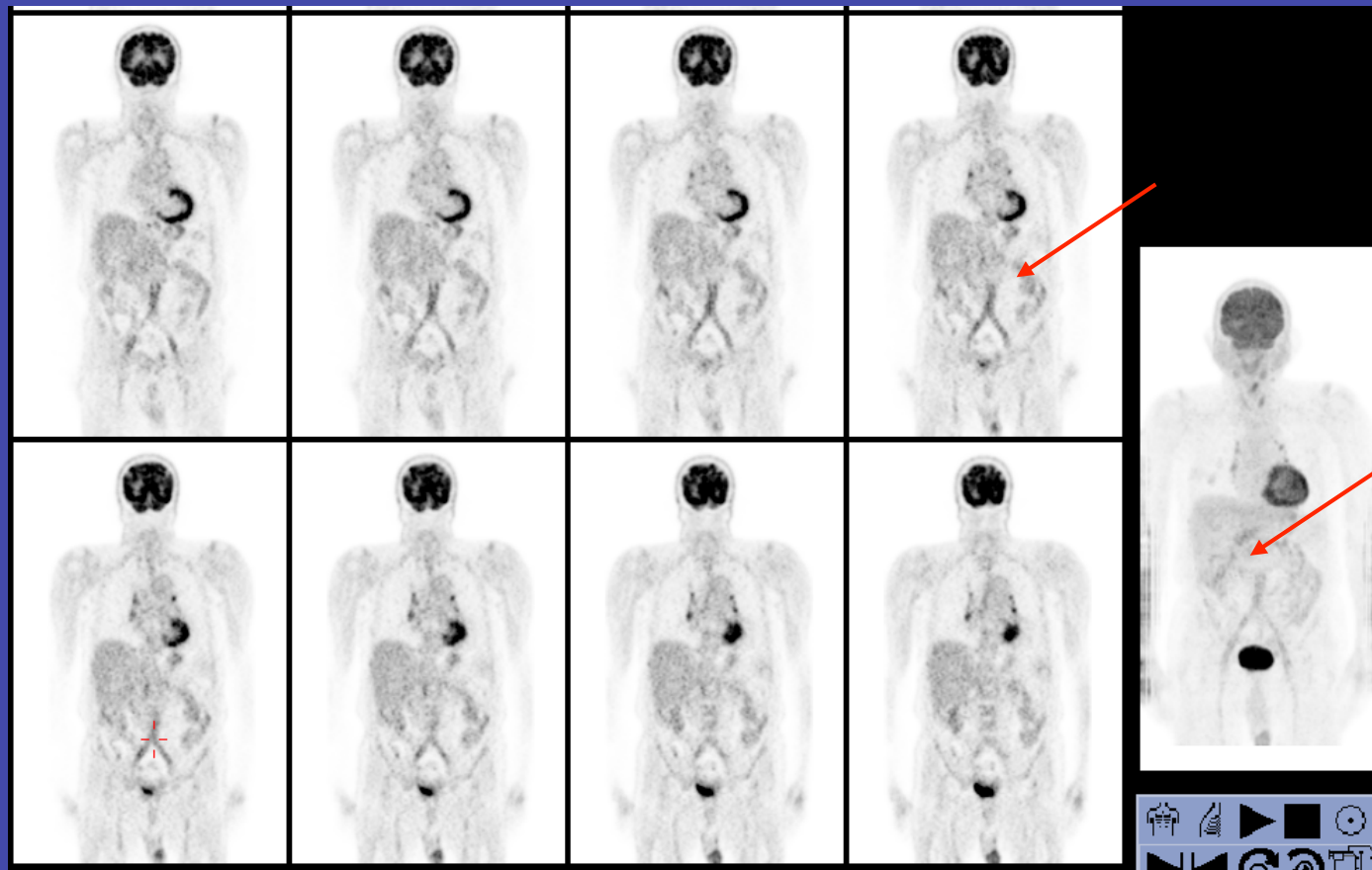
- 76 pts, 96 grafts
- PET – FDG+:
 - Presence
 - Intensity (& graft/blood): **high**
 - Pattern: **focal** vs. diffuse
- CT:
 - Anastomotic aneurysm
 - **irregular boundaries**
- High intensity, focal & irregular boundaries: **PPV 97%**
- Smooth boundaries, no focal uptake: **PPV <5%**
- Equivocal: inhomogenous FDG + & irregular CT lesion: **PPV 78%**

“Excellent diagnostic modality”

FDG Uptake in Non-Infected Prosthetic Vascular Grafts

Pattern: diffuse, linear, along graft path

- Foreign body reaction
- Inflammatory response to normal post-operative course



21 years
after implant

FDG - PET/CT

Evaluation of Infected Vascular Graft

Pitfalls & Limitations

- non-infected grafts: mild, linear, diffuse FDG uptake - ? low grade foreign body-related inflammatory reaction
- FDG+ in post-surgical inflammation, scar & native vessels
- FDG+ foci of adjacent soft tissue infection

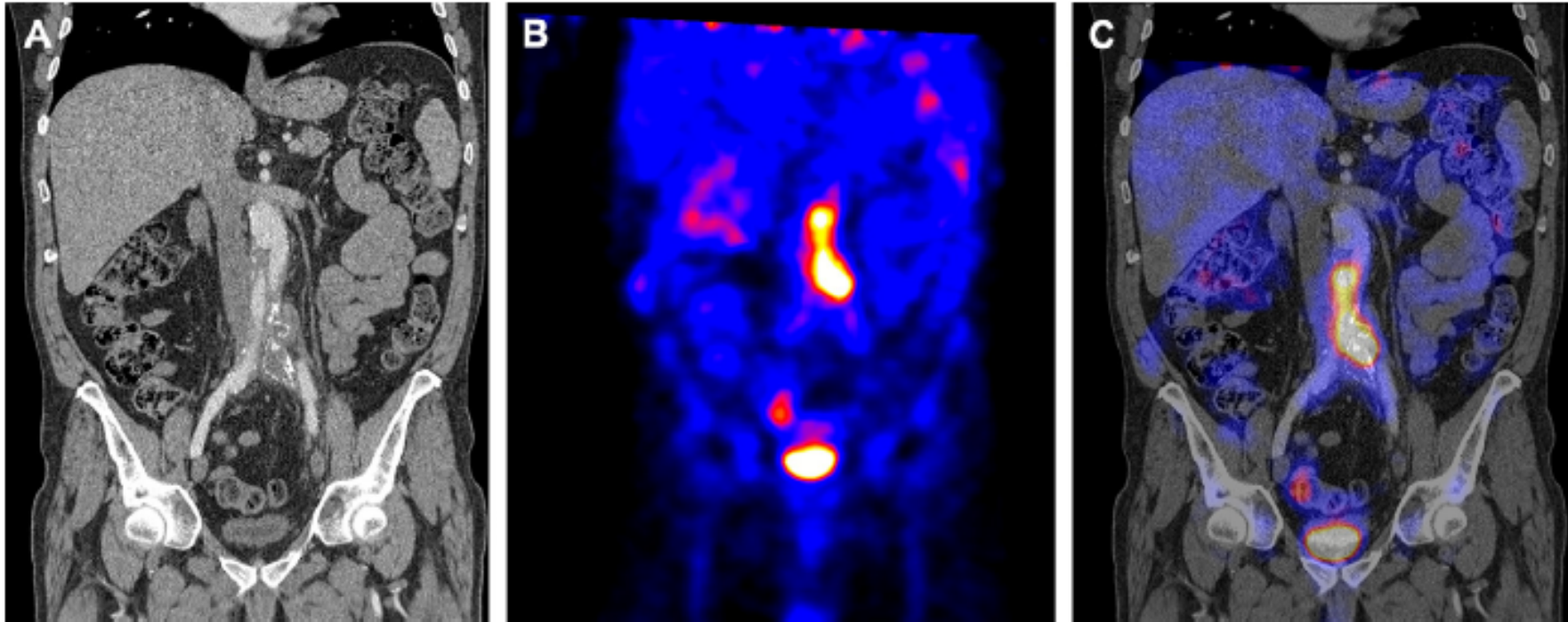
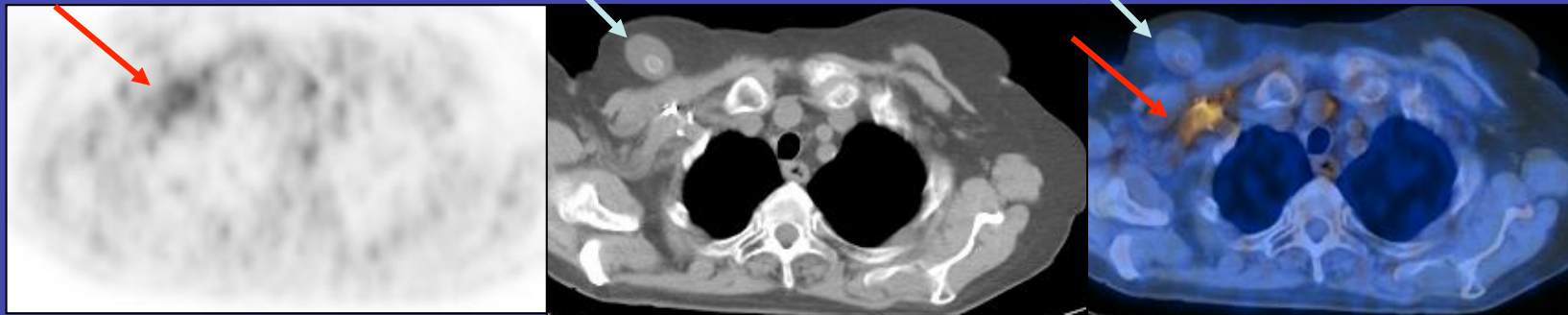
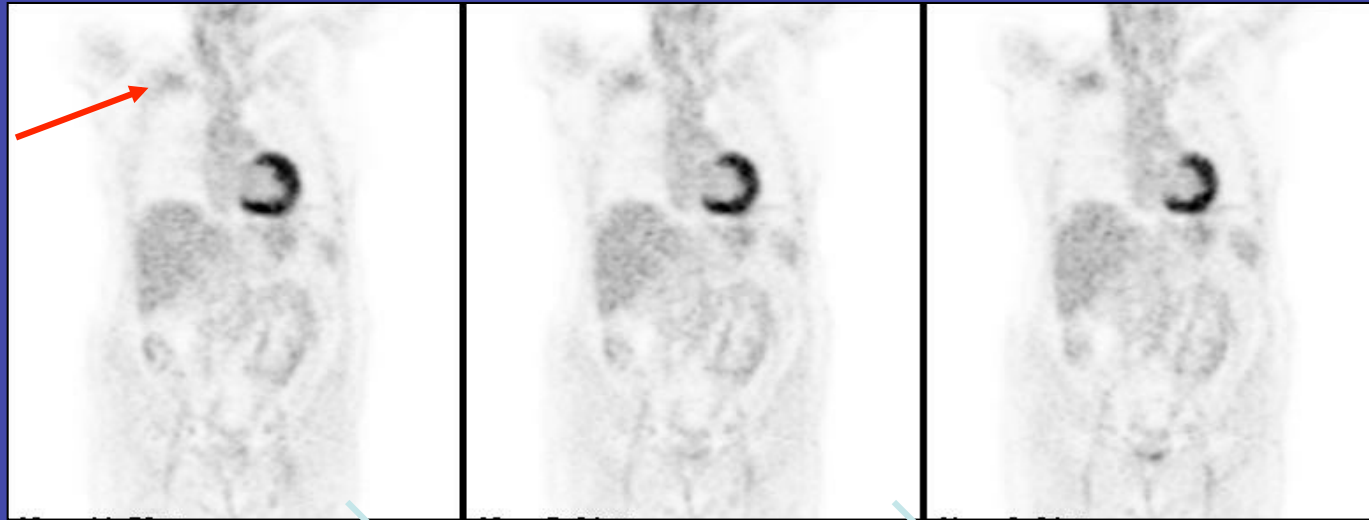

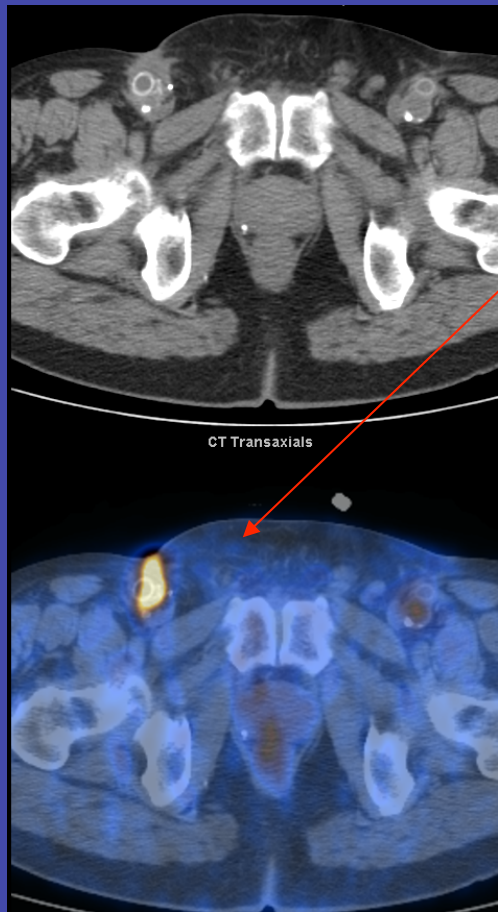
Fig. 1. Fifty-eight-year-old male patient, who suffered Q-fever (*Coxiella burnetii*) causing an infected aorto-iliac Dacron prosthesis, which had been inserted seven months before during exclusion of an inflammatory abdominal aortic aneurysm (A. CT image, B. PET image, and C. Fused PET-CT).

F, 64, s/a rt. axillo-femoral bypass
Swelling in rt. infra-clavicular region
Suspected infected graft

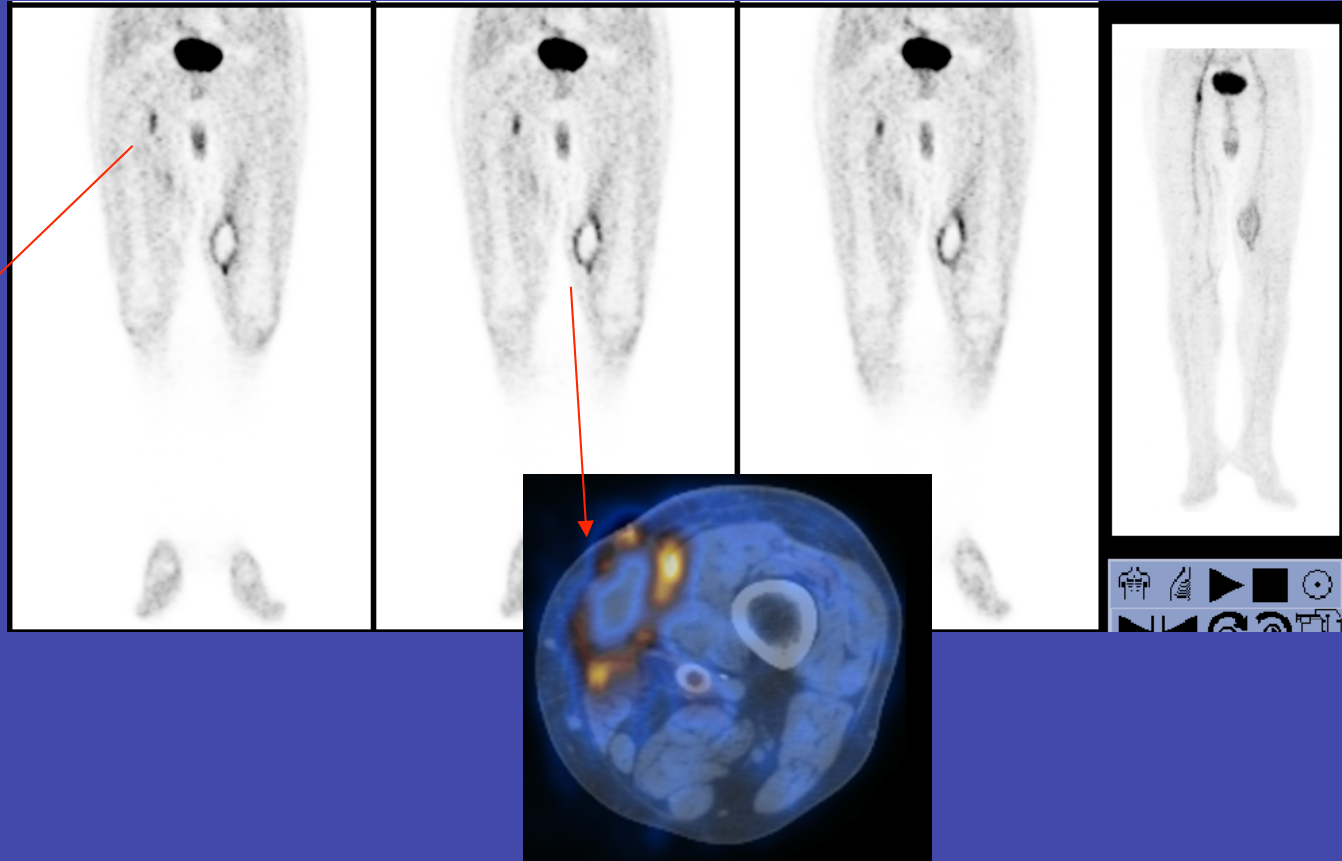


Exclusion – Non-infected graft – Seroma
FDG uptake in post-surgical changes

M, 65, s/a rt. fem-pop x 2, lt. fem-pop, aorto-fem grafts
s/a revision lt. graft -1 mo, infected wound rt. groin



Infected anastomosis

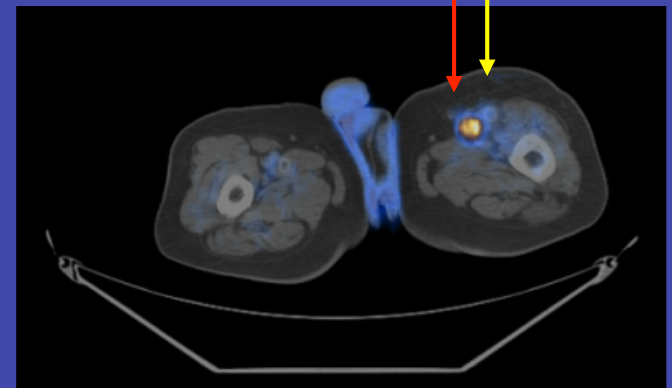
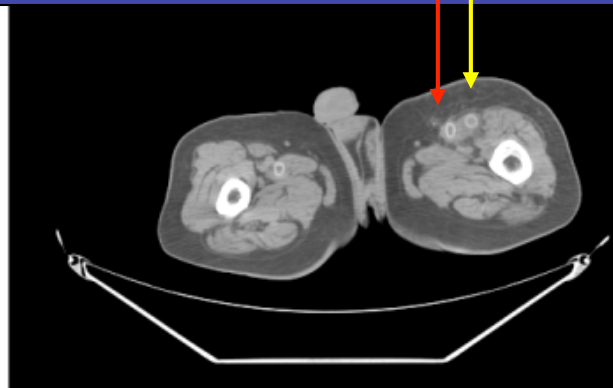
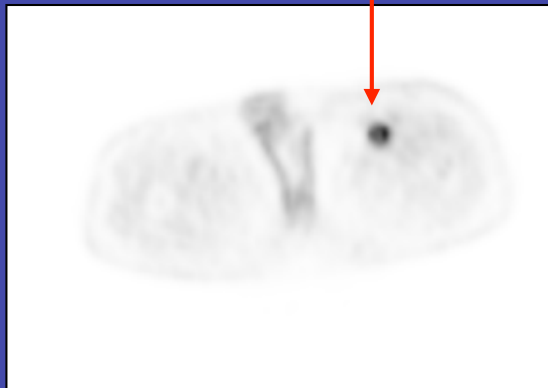
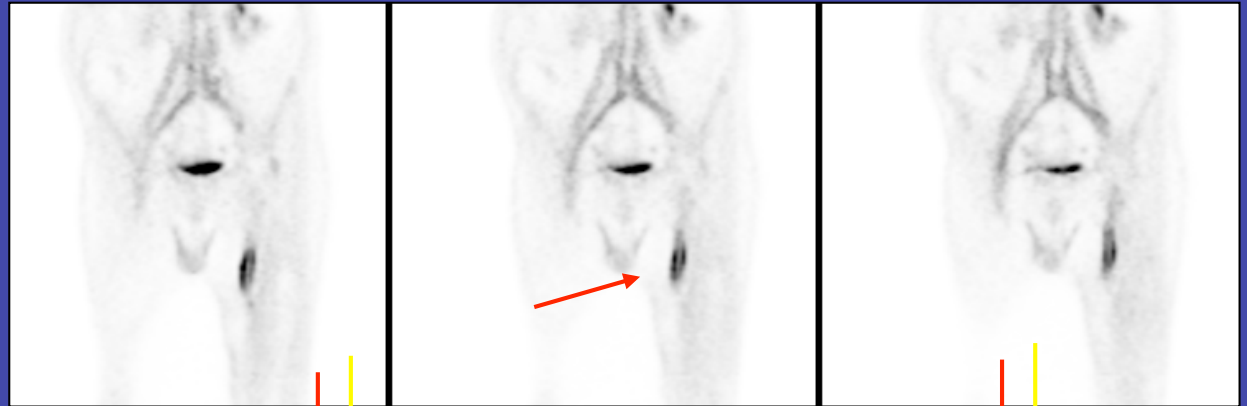
Hematoma after
recent surgery

Multiple Grafts

S/a aorto-bifem & lt. fem-pop graft - susp. infection

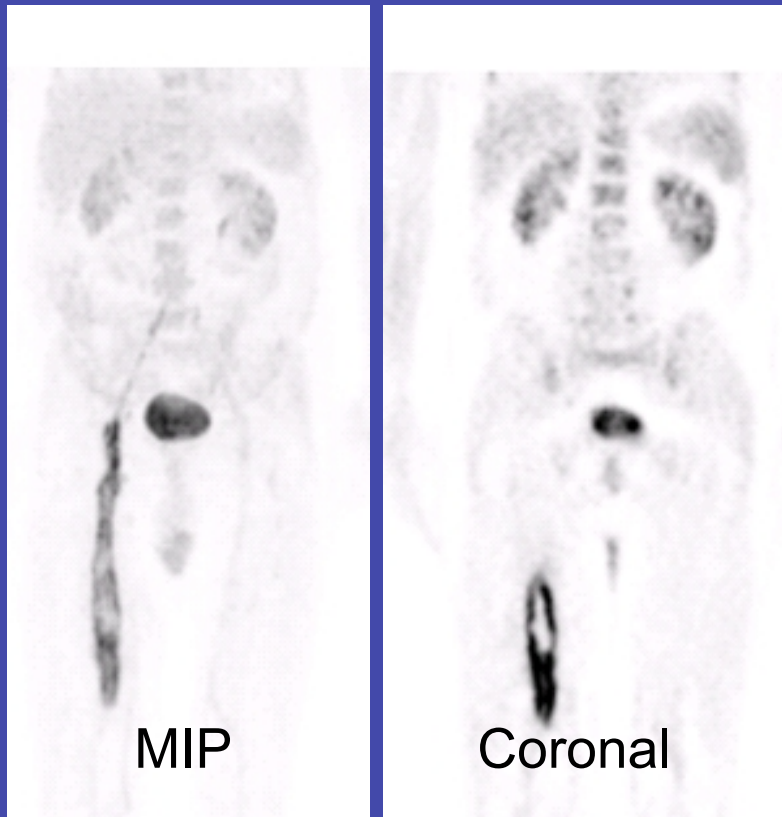
FDG-PET: Infection
Graft involvement?
Which graft?



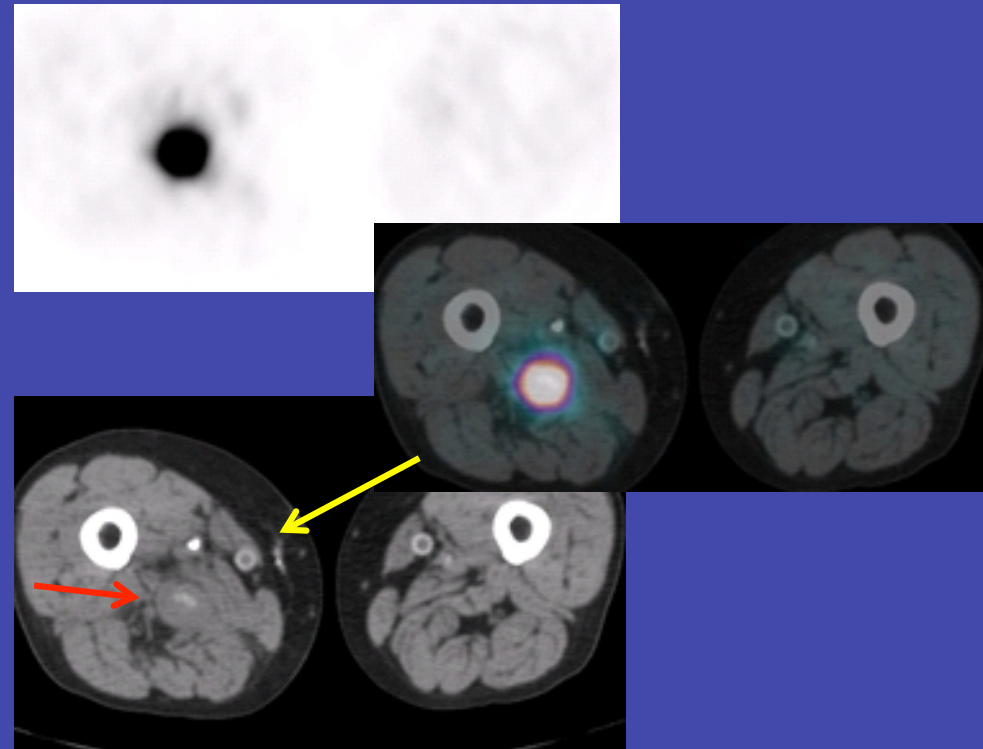
FDG-PET/CT:
Infected Femoro-popliteal graft
Planning of Surgery

Multiple Graft Implants

M, 65, s/a aorto-bi-fem, 2 x rt. fem-pop, lt. fem-pop & fem-fem grafts - fever, rt. thigh swelling, local pain

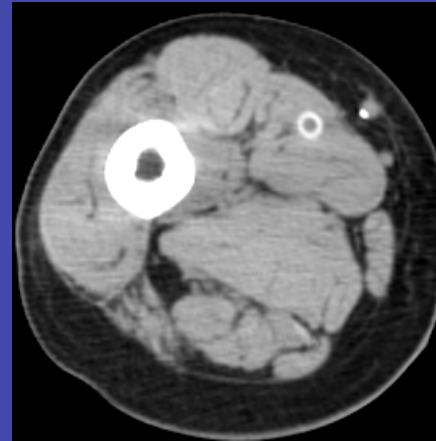
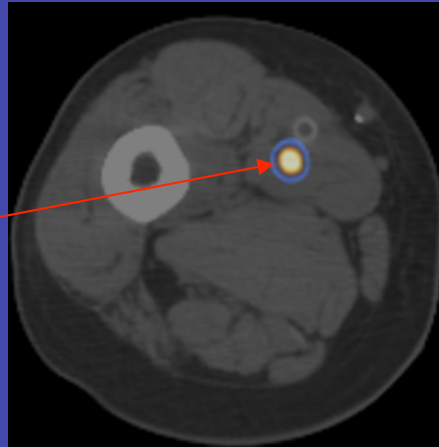
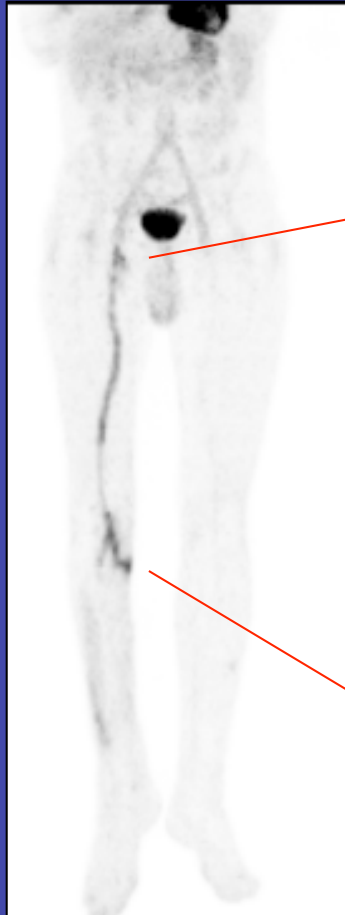

Linear intense FDG activity along medial aspect rt. thigh



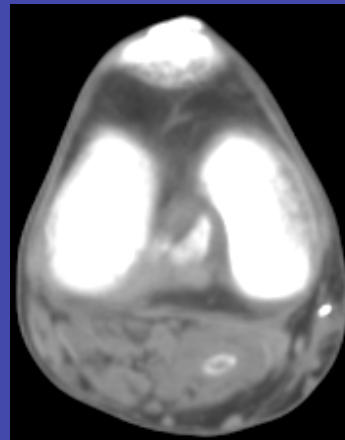
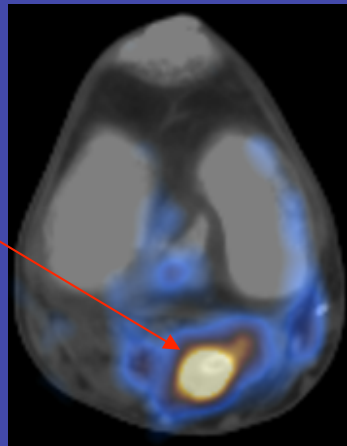
Infected original rt. fem-pop bypass & hypodense soft tissue abscess
Confirmed at surgery

s/a rt. femoro-popliteal goretex graft -10 mo,
infected surgical wound at distal anastomosis



Focus - Lt. upper thigh

FDG+ in soft tissue
No graft involvement



Focus - Lt. upper calf

FDG+ focus involving graft
& soft tissues

SUMMARY

- VGI: descriptives, causes, risk factors
- Clinical presentation
- **Diagnosis**
 - Morphological imaging
 - Functional imaging
 - SPECT/CT
 - **PET/CT**
 - Clinical data
 - Interpretation: pitfalls
 - **Challenging situations**
- Conclusions

Graft Infection, FDG Imaging Diabetes /Hyperglycemia

- Diabetes mellitus incidence of 7-8% in western countries (up to 18% > 65y)
- DM: increases incidence & severity of limb ischemia (x 2- 4)
- Graft patency rates after surgical revascularization similar in DM & non-DM
- DM: Greater rate of limb loss due to - persistent foot infection & necrosis
- DM: Higher risk of perioperative events

FDG, Infection, Diabetes & Hyperglycemia Specific Considerations

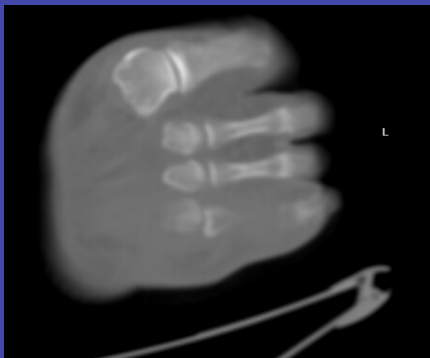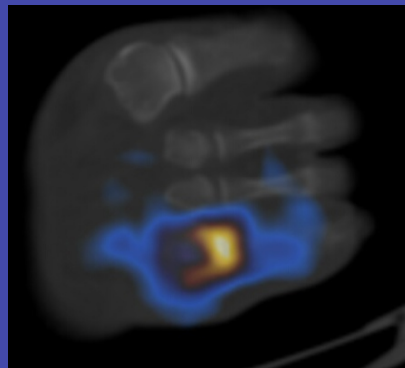
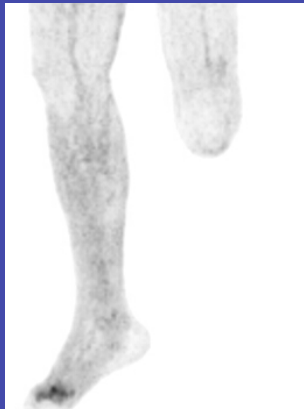- Hyperglycemia occurs frequently, in diabetics, after administration of steroids or chemotherapy
- Unclear/controversial impact of hyperglycemia on FDG imaging of cancer
- Unknown effect of hyperglycemia and diabetes on FDG imaging in infection

To assess whether hyperglycemia and diabetes affect the diagnostic accuracy of FDG-imaging of infection as compared with assessment of malignancy

Hyperglycemia , Diabetes, FDG, Infection

Diabetic foot
blood glucose - 190 mg/dl

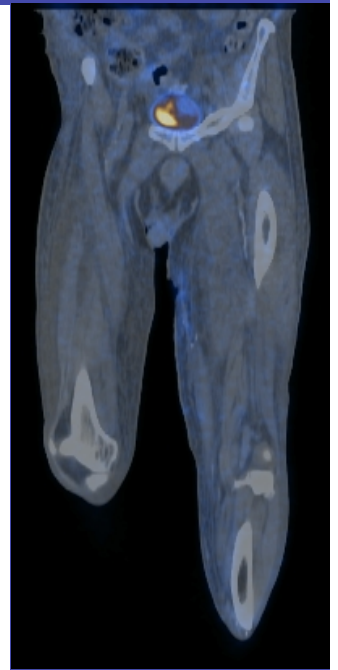
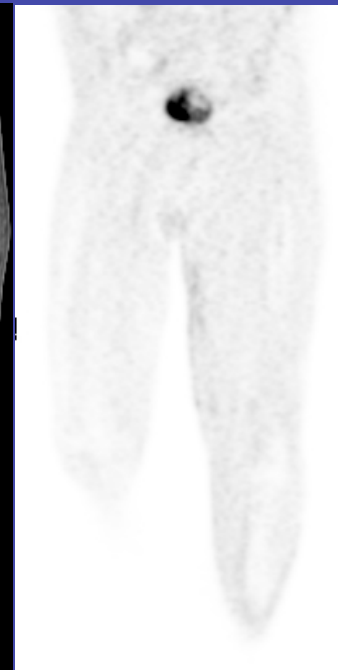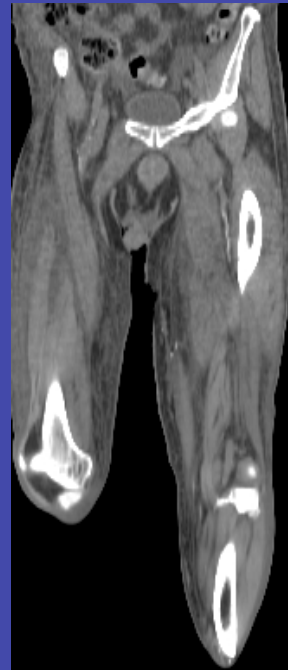
TP study



Osteomyelitis 4th metatarsus

Diabetic patient
blood glucose - 84 mg/dl

FN study



Infected, pus secreting
wound

FDG-PET/CT Accuracy in Hyperglycemic & Diabetes

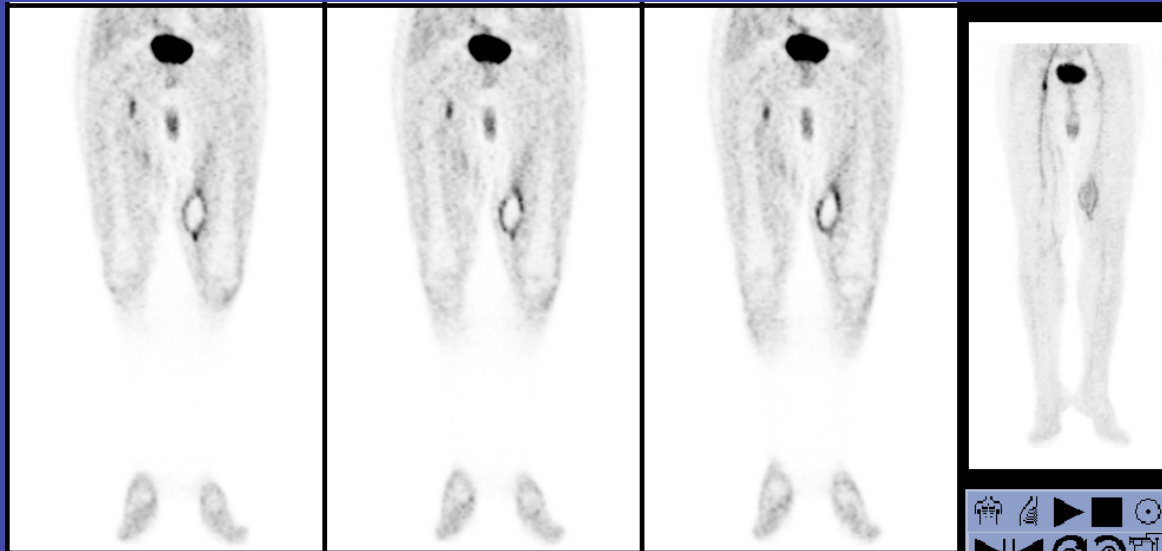
[Infection, n=123; Cancer, n= 320]

	Infection & Inflammation		Cancer		p
	No. pts	False negative rate	No. pts	False negative rate	
Hyperglycemia	19/123	0/11 (0%)	84/320	6/56 (10%)	NS
Normo-glycemia	104/123	4/54 (7%)	236/320	7/181 (4%)	NS
P		NS		P<0.05	
Diabetes Mellitus	42/123	2/26 (8%)	183/320	8/122 (7%)	NS
No diabetes	83/123	2/39 (5%)	137/320	5/115 (4%)	NS
P		NS		NS	

- High glucose levels but not DM affected FDG-PET/CT detection rate of cancer (p<0.05)
- Neither DM nor hyperglycemia had a significant impact on the false negative rate of FDG imaging in infection

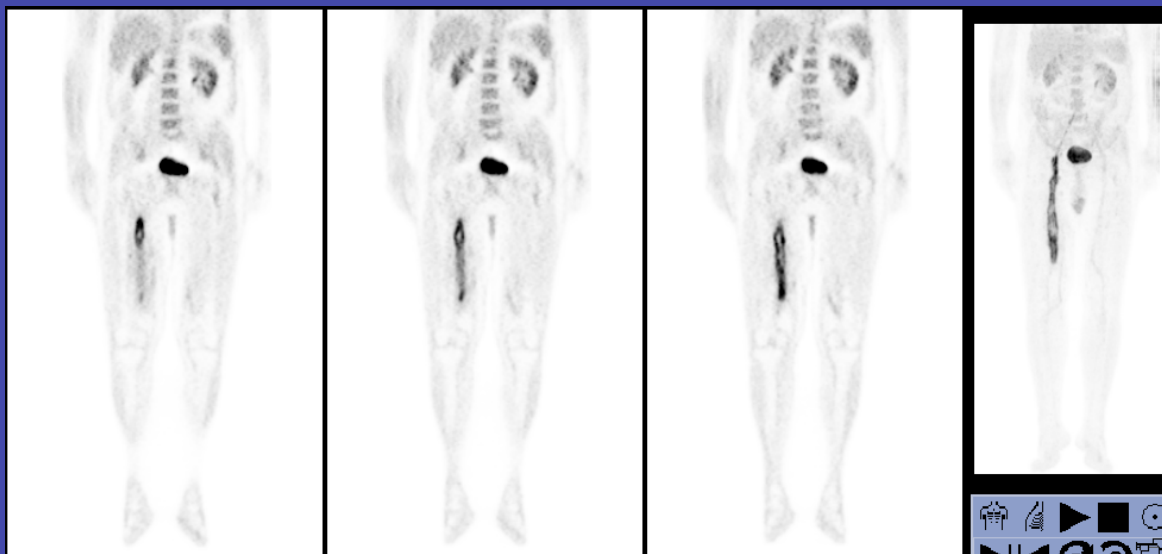Monitoring the course of disease

M, 65, s/a rt. fem-pop x 2, lt. fem-pop, aorto-fem grafts
10 mo follow up



1/2007

Infected graft &
postsurgical
hematoma



11/2007

Extensive graft
involvement &
resolution of
hematoma

SUMMARY

- VGI: descriptives, causes, risk factors
- Clinical presentation
- Diagnosis
 - Morphological imaging
 - Functional imaging
 - SPECT/CT
 - PET/CT
 - Clinical data
 - Interpretation: pitfalls
 - Challenging situations
- **Conclusions**

FDG-PET/CT

Important Clinical Role in Assessment of Suspected Vascular Graft Infection

- Improved image interpretation (better localization)
- Higher diagnostic confidence
- Improved clinical decision making
- Better patient management

PET/CT – at present the better modality

Reconsider the role of SPECT/CT with future improved technology (software & hardware)

FDG-PET/CT in VGI :

- Allows the diagnosis of infection
- Localizes & differentiates infection
 - graft vs. adjacent soft tissue
- Localizes infection to specific graft
 - if two or more adjacent grafts
- Excludes graft infection
 - localizing FDG uptake to non-specific, inflammatory process

Avoids further debilitating, life threatening consequences (related to disease or treatment).

Thank you for your
attention!