

Shouldering the blame for impingement: the rotator cuff continuum

J van Zuydam^{a,b*}, DC Janse van Rensburg^{a,c}, CC Grant^{a,c}, A Janse van Rensburg^{a,c} and J Patricios^{a,c,d}

^aFaculty of Health Sciences, University of Pretoria

^bMorningside Sports Medicine, Johannesburg

^cExercise SMART TEAM

^dFaculty of Health Sciences, University of the Witwatersrand

*Corresponding author: Jarrad van Zuydam, e-mail jarra@gmail.com

Abstract

The aim of this article was to summarise recent research on shoulder impingement and rotator cuff pathology. A continuum model of rotator cuff pathology is described, and the challenges of accurate clinical diagnosis, imaging and best management discussed.

Keywords: shoulder impingement syndrome, subacromial impingement syndrome, rotator cuff, tendinopathy, rehabilitation

Introduction

There are substantial differences in the reported prevalence of shoulder pain in the general population. The complaint is a common one, not only in sports and exercise medicine, but also in family practice. A systematic review concluded that one-month prevalence was 18.6-31.0%, one-year prevalence 4.7-46.7%, and the lifetime prevalence of shoulder complaints to be as high as 66.7%.¹ Shoulder pain is the second most common reason for referral to orthopaedic and sports specialist centres,² and 41% of these patients have persistent pain 12 months after presentation.³ Rotator cuff tendinopathy and shoulder impingement syndrome (SIS) are the most frequent causes of shoulder pain. These conditions are shown to reduce health and cause significant disability by reducing functional status.⁴ This article aims to equip the primary care physician with the knowledge to be able to recognise the signs and symptoms of SIS, understand its underlying pathology and to institute the correct investigations and management.

Impingement

"Shoulder impingement" is a popular clinical diagnosis, but perhaps it should not be thought of as a diagnosis at all. Rather, it refers to the findings of a provocative physical examination that could be produced by a variety of subacromial pathologies, including subacromial bursitis, partial rotator cuff tears, biceps tendinitis, scapular dyskinesia, a tight posterior capsule and postural abnormalities.⁵ SIS can be defined as compression of the rotator cuff and the subacromial bursa against the antero-inferior aspect of the acromion and the coracoacromial ligament that leads to pain and/or weakness around the shoulder joint, especially with overhead activity.⁶

Table I lists the differential diagnoses which should be considered when a patient presents with the signs and symptoms of shoulder impingement.

Table I: The differential diagnosis of shoulder impingement syndrome

Condition	Clinical features
Glenohumeral osteoarthritis	Pain and stiffness aggravated by activity. Look for a characteristic osteophyte at the inferior aspect of the humeral head.
Glenohumeral instability	A positive apprehension test. The subacromial injection of lignocaine does not relieve the symptoms of glenohumeral instability.
Referred pain	Examine the cervical and thoracic spine, as well as the myofascial structures.
Adhesive capsulitis ("frozen" shoulder)	This is more common in the left shoulder, in women aged 40-60 years and in diabetics. It presents with shoulder stiffness and limited passive external rotation on examination.
Acromioclavicular joint arthritis or injury	Tenderness over the acromioclavicular joint, positive scarf test and relief of the symptoms through the injection of 2-5 ml of lignocaine into the acromioclavicular joint.
Nerve entrapment syndrome	Suprascapular or long thoracic nerve palsy.
Glenoid labral tears	Vague, deep-seated shoulder pain, possibly associated with clicking, catching or popping. A positive O'Brien's test.
Biceps tendinopathy	Pain and tenderness over the bicipital groove and a positive Speed's test.

Impingement is traditionally divided into external impingement and internal impingement groups, with the external impingement group being subdivided into primary and secondary subgroups. Primary external impingement implies abnormalities of the superior bony structures, leading to encroachment of the subacromial space from above. An abnormally shaped acromion is often the cause, but an acromial bony spur may occur in older age groups (Figure 1).⁷

Secondary external impingement refers to narrowing of the subacromial space by anterior tilt and excessive internal rotation

of an unstable scapula.⁹ Weakness and inactivity of the scapular stabilising muscles leads to an abnormal scapulohumeral rhythm. Physical examination of the painful shoulder is not complete without an assessment of scapular position and motion.

Internal impingement occurs due to repetitive microtrauma to the rotator cuff tendons (predominantly supraspinatus) in athletes who engage in throwing, racquet or other overhead actions.¹⁰ Extension, abduction and external rotation of the humerus causes impingement of the supraspinatus and infraspinatus tendons on the posterosuperior glenoid rim in these athletes.

It is important to recognise that primary and secondary external impingement may not occur in isolation. Underlying scapular dyskinesis may worsen the impingement which is already taking place due to a hooked acromion.

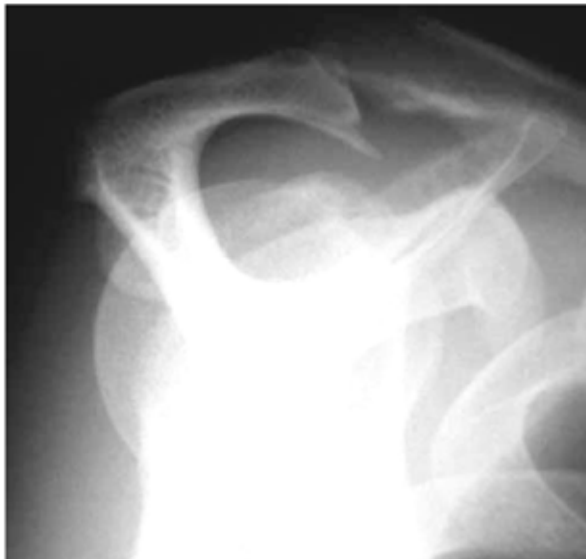

Figure 1: Plain radiograph of a type III acromion with a prominent acromial enthesophyte⁸

Neer classically described three stages of the impingement process.¹¹ The first stage involves acute bursitis with subacromial oedema and hemorrhage. In the second stage, the bursa eventually no longer lubricates the underlying rotator cuff, leading to tendinopathy of the rotator cuff tendons, which may include the development of partial-thickness tears of the supraspinatus tendon. The third stage is characterised by the progression of a partial-thickness tear to a full-thickness tear.¹²

A continuum

In 2009, Cook and Purdham¹³ proposed a continuum model of pathology in tendinopathy in a benchmark article. Their model has become widely accepted as an explanation of the clinical presentation of generic load-induced tendinopathy at different stages. The Cook and Purdham model describes the progression from a normal tendon to reactive tendinopathy, to tendon disrepair, and ultimately to degenerative tendinopathy. The stages of reactive tendinopathy and tendon disrepair are potentially reversible, while degenerative tendinopathy is currently irreversible.

Lewis¹⁴ adapted the Cook and Purdham model to apply specifically to the rotator cuff by providing clinical and imaging characteristics, as well as appropriate management strategies for each stage. Lewis' model for rotator cuff pathology is outlined in Figure 2.

Reactive rotator cuff tendinopathy is an oedematous, overloaded tendon that causes pain on activity. Persistent pain and night pain may raise the suspicion of subacromial bursal inflammation.¹⁵

The rotator cuff tendon is substantially overloaded and displays incomplete healing in the stage of tendon disrepair. The oedematous tendon may have degenerated to a small partial-thickness tear.

Degenerative tendinopathy manifests in large partial- and full-thickness rotator cuff tears, as well as massive rotator cuff tears which cannot heal. Pain may or may not be present at this stage,

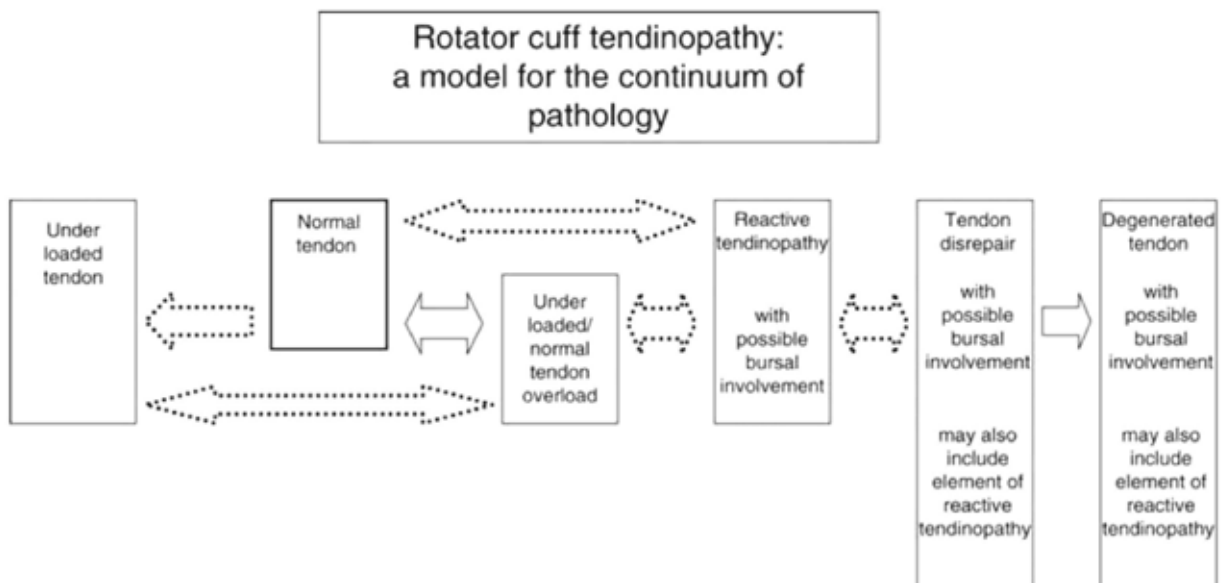


Figure 2: A model of the continuum of rotator cuff pathology¹⁴

but significant weakness is evident in the case of complete rotator cuff tears.

Clinical features

The patient with rotator cuff pathology complains of anterior or lateral shoulder pain when using overhead actions, such as throwing, swimming or even pulling on a jersey. Activities performed at less than 90° of abduction are usually pain free.¹⁶ Night pain is a common complaint in this patient group, and patients may reveal that they are unable to lie on the affected shoulder at night. Shoulder pain, which awakens the patient at night, should alert the clinician to a possible rotator cuff tear or subacromial bursitis.¹⁵ Pain receptors in the shoulder region are located in the rotator cuff muscles and tendons, the subacromial bursa, the glenohumeral joint and in the coracoacromial ligament.¹⁷ Tenderness is most often concentrated over the supraspinatus tendon proximal to or at the greater tuberosity of the humerus, but is commonly difficult to localise. Anterolateral shoulder pain and tenderness may be experienced due to an inflamed subacromial bursa which extends beyond the lateral border of the acromion. The strength of all four rotator cuff muscles should be assessed separately and compared to the asymptomatic side before consideration is given to more specific physical examinations. Pain on resisted movement may be prominent in reactive tendinopathy and tendon disrepair. However, noticeable weakness may indicate a complete rotator cuff tear.

Assessment of the shoulder joint requires a practised, systematic approach incorporating a wide array of physical tests.¹⁸ Recent systematic reviews and meta-analyses have provided clues as to which of these tests might be the most sensitive and specific to diagnose rotator cuff pathology and SIS.¹⁹⁻²¹ The Hawkins-Kennedy test (sensitivity 74% and specificity 57%), Neer's test (sensitivity 78% and specificity 58%), and the empty can test (sensitivity 69% and specificity 62%) all have higher sensitivities than specificities for SIS. A low likelihood of SIS is indicated in a patient when these three tests are negative. Therefore, they are useful for ruling out a diagnosis of SIS, but are not particularly specific when positive. Of the three, Neer's test has the highest pooled sensitivity, making it particularly useful in eliminating a suspicion of SIS. The drop arm test (sensitivity 21% and specificity 92%) and the lift-off test (sensitivity 42% and specificity 97%) have

higher specificities, making them more useful for ruling in SIS, if one or both are positive.¹⁹ A rotator cuff tear can be suspected (sensitivity 49% and specificity 95%) in a patient aged 65 years or older with weakness of external rotation (positive infraspinatus test) and night pain.²² A positive lift-off test and/or weakness in internal rotation are useful in diagnosing tendinopathy or a tear of the subscapularis.²³ Table II describes the aforementioned individual tests.

Imaging

In general, a good clinical examination is initially sufficient with respect to patients with suspected SIS or other rotator cuff pathology, but imaging may be appropriate when the diagnosis is not clinically clear, and in those who do not respond to appropriate initial conservative treatment.²⁵ Plain radiography is useful when excluding other causes of shoulder pain, such as calcific tendinopathy or cervical radiculopathy. Routine radiographs for suspected rotator cuff pathology or impingement include anteroposterior and Grashey views, as well as outlet and axillary views. X-rays of the cervical spine should be included to assess for signs of cervical radiculopathy. A plain X-ray of the shoulder is used to assess the morphology of the acromion, in order to classify it as type I (flat), type II (curved) or type III (hooked), as described by Bigliani.²⁶ A higher incidence of cuff tears has been associated with type III acromial morphology,^{27,29} although the acromial shape has since been shown to be a poor descriptor of subacromial space narrowing.²⁹ Plain radiographs may also reveal acromioclavicular osteoarthritis with inferior osteophyte formation, acromial enthesophytes or sclerosis, and cystic changes of the humeral head. It should be noted that these features may be present in asymptomatic subjects, making the relationship of such findings to the diagnosis of impingement controversial.¹²

Advanced imaging may be necessary for a definitive diagnosis in some cases. An ultrasound (US) scan and magnetic resonance imaging (MRI) have been shown to be equally highly sensitive in diagnosing rotator cuff pathology,²⁵ although an US scan may be more operator dependent. A US scan has the advantage of being a dynamic study, allowing the sonographer to place the arm in a position of impingement during the examination. MRI should perhaps be considered the gold standard for its superiority in diagnosing glenoid labral tears, partial-thickness cuff tears and

Table II: A description of the available clinical tests when assessing the presence of shoulder impingement syndrome

Clinical test	Description	Positive sign
Hawkins-Kennedy test	The arm is placed in 90° of forward flexion, and gently internally rotated to resistance. The examiner stabilises the scapula with the other hand. ²⁴	Pain
Neer's test	The examiner fixes the ipsilateral scapula and passively forward flexes the arm to resistance. ²³	Pain, relieved by an injection of up to 10 ml lidocaine beneath the anterior acromion
Empty can test	With the shoulder in 90° of abduction, 30° of horizontal adduction and full internal rotation, the patient attempts to resist downward force applied by the examiner. ²⁴	Weakness
Drop arm test	The patient actively fully abducts the arm, and then slowly adducts the arm in the same arc. ²⁴	The arm drops suddenly (due to weakness or severe pain)
Lift-off test	The patient places the dorsum of his or her hand on his or her ipsilateral buttock by internally rotating at the shoulder. The patient is then asked to push backwards against the resistance applied by the examiner. ²⁰	Weakness

subacromial bursal effusion and hypertrophy.²⁵ The injection of contrast at the time of the MRI to perform a magnetic resonance arthrogram further enhances its sensitivity with respect to glenoid labral lesions and partial-thickness cuff tears. However, given the large difference in the cost between the two modalities, a US scan may be the most cost-effective diagnostic method in experienced hands.³⁰

Management

Conservative treatment is successful in most patients. Patients must always be advised on strict avoidance of any provocative manoeuvres. These include overhead movements, such as those utilised when swimming, serving in tennis or throwing. Cummins, Sasso and Nicholson³¹ reported on the results of 100 consecutive patients with SIS treated by way of a non-surgical treatment protocol, consisting of a subacromial cortisone injection and physical therapy. Seventy-nine per cent of these patients did not require surgical treatment after a two-year follow-up. The total number of subacromial cortisone injections and the patient response to the initial injection were shown to be predictors of future surgical intervention. There is no level 2 evidence to support nonsteroidal anti-inflammatory drugs, therapeutic US, interferential stimulation, laser, magnetic field therapy or local massage. A single subacromial corticosteroid injection is supported by level 2 evidence for short-term treatment,³² but seems to carry some risk of toxicity to the tendon,³³ and may only hit the mark 70% of the time.³⁴ Similarly, the application of glyceryl trinitrate patches to the site of maximal tenderness is also supported by level 2 evidence, and may be a useful adjunct in conservative management.^{35,36}

Increasingly, exercise is recognised as a mainstay in the treatment of SIS and rotator cuff pathology. Through a systematic review of the literature, Kuhn⁵ demonstrated that exercise has statistically and clinically significant effects on pain reduction and improving function, but not on range of motion or strength. He also formulated an evidence-based "gold standard" exercise rehabilitation protocol for rotator cuff impingement, consisting of flexibility, range-of-motion and strengthening exercises. Exercise therapy, combined with manual therapy, may be more beneficial than exercise therapy alone.³⁷ Patients with SIS should consult a physiotherapist who is experienced in treating shoulder pain and well versed in the latest rehabilitation protocols.

Although some evidence exists to support the use of exercise in the management of full-thickness and massive rotator cuff tears,³⁸ these patients may need surgical treatment to relieve their symptoms. Also, patients with a type III acromion may not respond well to conservative therapy owing to the anatomical pathogenesis of their symptoms. With the evolution of arthroscopic shoulder surgery, open anterior acromioplasty has evolved into arthroscopic subacromial decompression procedures, involving arthroscopic acromioplasty and subacromial bursectomy.¹² Patients treated with arthroscopic acromioplasty return to work sooner and have shorter hospital stays than those who undergo an open procedure.³⁹

Conclusion

Shoulder pain is a common and disabling condition. Shoulder impingement is a clinical sign of underlying subacromial pathology, most often caused by rotator cuff tendinopathy. Rotator cuff tendinopathy may be viewed as proceeding along stages in a continuum, from reactive tendinopathy to irreversible degenerated tendon. Specific clinical tests have proven to be sufficiently sensitive in diagnosing SIS. However, appropriate plain X-rays, a dynamic US scan and MRI may be necessary to confirm the diagnosis. Exercise rehabilitation should be considered the mainstay of treatment for all stages of the disease. Subacromial steroid injection and glyceryl trinitrate patches should be contemplated in most cases before proceeding to arthroscopic surgical management.

A summary of the practice essentials when treating shoulder impingement

- Shoulder impingement is a clinical sign of underlying subacromial pathology.
- Rotator cuff tendinopathy may be conceptualised as a continuum of worsening pathology.
- A practised and careful physical examination of the shoulder can raise suspicion or exclude the diagnosis of shoulder impingement syndrome.
- MRI is the gold standard imaging technique. However, a US scan is cheaper and almost as accurate in experienced hands.
- An appropriate exercise rehabilitation programme should be instituted for every patient.
- Subacromial steroid injections and glyceryl trinitrate patches may offer short-term relief of the symptoms.
- Shoulder surgery is the last resort and is often successful with regard to large rotator cuff tears.

References

1. Luime JJ, Koes BW, Hendriksen IJM, et al. Prevalence and incidence of shoulder pain in the general population; a systematic review. *Scand J Rheumatol*. 2004;33(2):73-81.
2. Butcher JD, Zukowski CW, Brannen SJ, et al. Patient profile, referral sources, and consultant utilization in a primary care sports medicine clinic. *J Fam Pract*. 1996;43(6):556-560.
3. Van der Windt DA, Koes BW, Boeke AJ, et al. Shoulder disorders in general practice: prognostic indicators of outcome. *Br J Gen Pract*. 1996;46(410):519-523.
4. Ostor AJ, Richards CA, Prevost AT, et al. Diagnosis and relation to general health of shoulder disorders presenting to primary care. *Rheumatology (Oxford)*. 2005;44(6):800-805.
5. Kuhn JE. Exercise in the treatment of rotator cuff impingement: a systematic review and a synthesized evidence-based rehabilitation protocol. *J Shoulder Elb Surg*. 2009;18(1):138-160.
6. Hughes P, Green RA, Taylor NF. Measurement of subacromial impingement of the rotator cuff. *J Sci Med Sport*. 2012;15(1):2-7.
7. Ogawa K, Yoshida A, Inokuchi W, Naniwa T. Acromial spur: relationship to aging and morphological changes in the rotator cuff. *J Shoulder Elb Surg*. 2005;14(6):591-598.
8. Ilahi O. Shoulder impingement. Omer Ilahi, MD [homepage on the Internet]. 2011. c2014. Available from: <http://www.doctorilahi.com/shoulder-impingement>
9. Hebert LJ, Moffet H, McFadyen BJ, Dionne CE. Scapular behavior in shoulder impingement syndrome. *Arch Phys Med Rehabil*. 2002;83(1):60-69.
10. Myers JB, Laudner KG, Pasquale MR, et al. Glenohumeral range of motion deficits and posterior shoulder tightness in throwers with pathologic internal impingement. *Am J Sports Med*. 2006;34(3):385-391.

11. Neer CS 2nd. Anterior acromioplasty for the chronic impingement syndrome in the shoulder: a preliminary report. *J Bone Joint Surg.* 1972;54(1):41-50.
12. Harrison AK, Flatow EL. Subacromial impingement syndrome. *J Am Acad Orthop Surg.* 2011;19(11):701-708.
13. Cook JL, Purdam CR. Is tendon pathology a continuum? A pathology model to explain the clinical presentation of load-induced tendinopathy. *Br J Sports Med.* 2009;43(6):409-416.
14. Lewis JS. Rotator cuff tendinopathy: a model for the continuum of pathology and related management. *Br J Sports Med.* 2010;44(13):918-923.
15. Santavirta S, Kontinen YT, Antti-Poika I, Nordstrom D. Inflammation of the subacromial bursa in chronic shoulder pain. *Arch Orthop Trauma Surg.* 1992;111(6):336-340.
16. Brukner P, editor. Brukner and Khan's clinical sports medicine. 4th ed. New York: McGraw-Hill Medical, 2012.
17. Dean BJ, Gwilym SE, Carr AJ. Why does my shoulder hurt? A review of the neuroanatomical and biochemical basis of shoulder pain. *Br J Sports Med.* 2013;47(17):1095-1104.
18. McFarland EG, Garzon-Muvdi J, Jia X, et al. Clinical and diagnostic tests for shoulder disorders: a critical review. *Br J Sports Med.* 2010;44(5):328-332.
19. Hegedus EJ, Goode AP, Cook CE, et al. Which physical examination tests provide clinicians with the most value when examining the shoulder? Update of a systematic review with meta-analysis of individual tests. *Br J Sports Med.* 2012;46(14):964-978.
20. Alqunae M, Galvin R, Fahey T. Diagnostic accuracy of clinical tests for subacromial impingement syndrome: a systematic review and meta-analysis. *Arch Phys Med Rehabil.* 2012;93(2):229-236.
21. Wright AA, Wassinger CA, Frank M, et al. Diagnostic accuracy of scapular physical examination tests for shoulder disorders: a systematic review. *Br J Sports Med.* 2013;47(14):886-892.
22. Litaker D, Pioro M, El Bilbelsi H, Brems J. Returning to the bedside: using the history and physical examination to identify rotator cuff tears. *J Am Geriatr Soc.* 2000;48(12):1633-1637.
23. Naredo E, Aguado P, De Miguel E, et al. Painful shoulder: comparison of physical examination and ultrasonographic findings. *Ann Rheum Dis.* 2002;61(2):132-136.
24. Moen MH, de Vos RJ, Ellenbecker TS, Weir A. Clinical tests in shoulder examination: how to perform them. *Br J Sports Med.* 2010;44(5):370-375.
25. Ardic F, Kahraman Y, Kacar M, et al. Shoulder impingement syndrome: relationships between clinical, functional, and radiologic findings. *Am J Phys Med Rehabil.* 2006;85(1):53-60.
26. Bigliani L. The morphology of the acromion and its relationship to rotator cuff tears. *Orthop Trans.* 1986;10:228.
27. Epstein RE, Schweitzer ME, Frieman BG, et al. Hooked acromion: prevalence on MR images of painful shoulders. *Radiology.* 1993;187(2):479-481.
28. Toivonen DA, Tuite MJ, Orwin JF. Acromial structure and tears of the rotator cuff. *J Shoulder Elb Surg.* 1995;4(5):376-383.
29. Mayerhoefer ME, Breitensteiner MJ, Wurnig C, Roposch A. Shoulder impingement: relationship of clinical symptoms and imaging criteria. *Clin J Sport Med.* 2009;19(2):83-89.
30. Shahabpour M, Kichouh M, Laridon E, et al. The effectiveness of diagnostic imaging methods for the assessment of soft tissue and articular disorders of the shoulder and elbow. *Eur J Radiol.* 2008;65(2):194-200.
31. Cummins CA, Sasso LM, Nicholson D. Impingement syndrome: temporal outcomes of nonoperative treatment. *J Shoulder Elb Surg.* 2009;18(2):172-177.
32. Blair B, Rokito AS, Cuomo F, et al. Efficacy of injections of corticosteroids for subacromial impingement syndrome. *J Bone Joint Surg.* 1996;78(11):1685-1689.
33. Dean BJ, Franklin SL, Murphy RJ, et al. Glucocorticoids induce specific ion-channel-mediated toxicity in human rotator cuff tendon: a mechanism underpinning the ultimately deleterious effect of steroid injection in tendinopathy? *Br J Sports Med.* 2014;48(2):1620-1626.
34. Kang MN, Rizio L, Prybicien M, et al. The accuracy of subacromial corticosteroid injections: a comparison of multiple methods. *J Shoulder Elb Surg.* 2008;17(1):561-566.
35. Cumpston M, Johnston RV, Wengler L, Buchbinder R. Topical glyceryl trinitrate for rotator cuff disease. Cochrane review. In: *The Cochrane Library*, Issue 3, 2009. Oxford: Update Software.
36. Paoloni JA, Appleyard RC, Nelson J, Murrell GA. Topical glyceryl trinitrate application in the treatment of chronic supraspinatus tendinopathy: a randomized, double-blinded, placebo-controlled clinical trial. *Am J Sports Med.* 2005;33(6):806-813.
37. Faber E, Kuiper JL, Burdorf A, et al. Treatment of impingement syndrome: a systematic review of the effects on functional limitations and return to work. *J Occup Rehabil.* 2006;16(1):6-24.
38. Ainsworth R, Lewis JS. Exercise therapy for the conservative management of full thickness tears of the rotator cuff: a systematic review. *Br J Sports Med.* 2007;41(4):200-210.
39. Davis AD, Kakar S, Moros C, et al. Arthroscopic versus open acromioplasty: a meta-analysis. *Am J Sports Med.* 2010;38(3):613-618.