

# **Breast reduction and mammoplasty: Indications, successes and cost implications.**



UNIVERSITEIT VAN PRETORIA  
UNIVERSITY OF PRETORIA  
YUNIBESITHI YA PRETORIA


Solly Selahle  
Plastic & Reconstructive Surgery



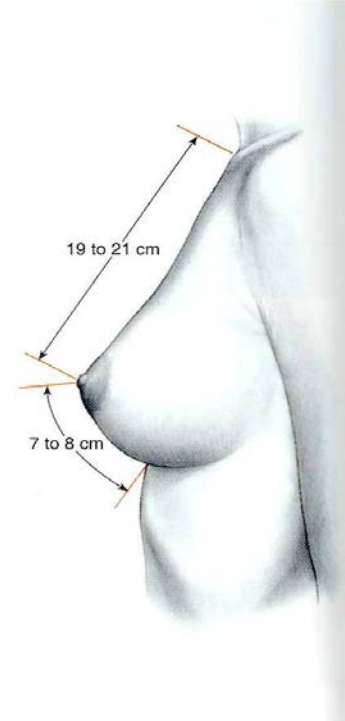
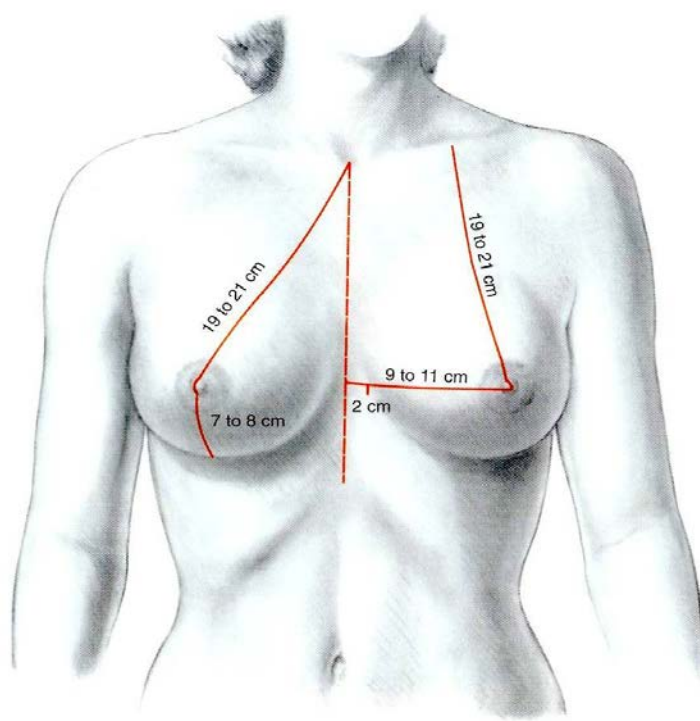
**Sir Harold Gillies:**

‘Plastic surgery is a constant battle between beauty and blood supply’

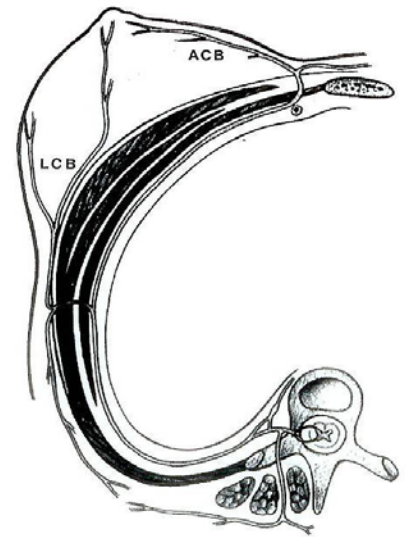
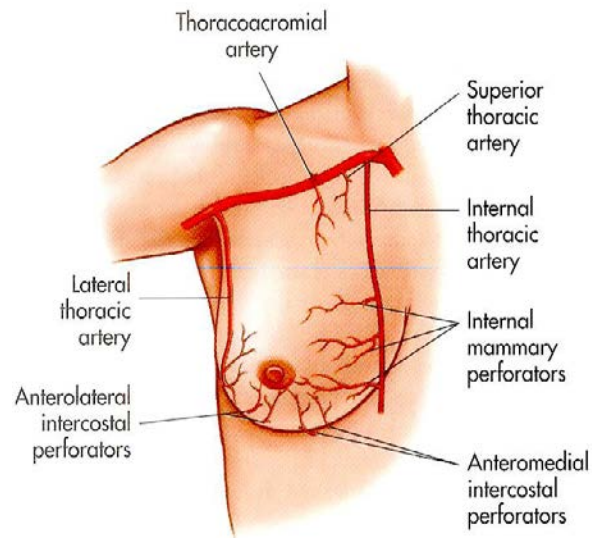
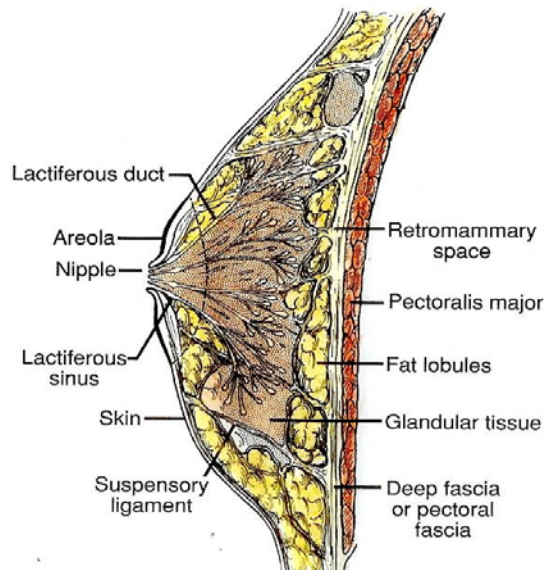
# Breast aesthetics



Jack Penn



# Anatomy



# Historical background

- **Early pioneers: removal of breast tissue**

- ✓ Setback : poor breast shape + breast scarring

- **NAC translocation procedures :**

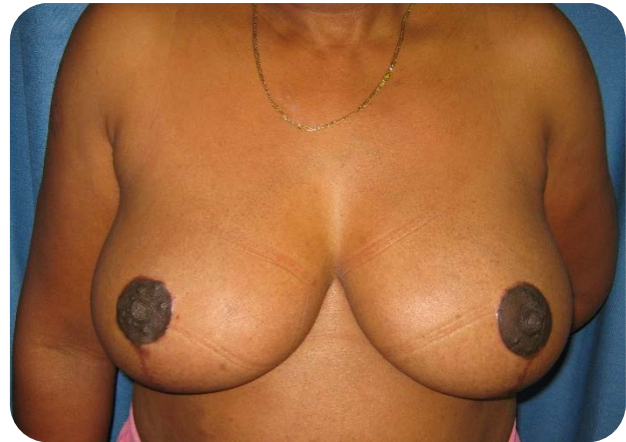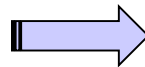
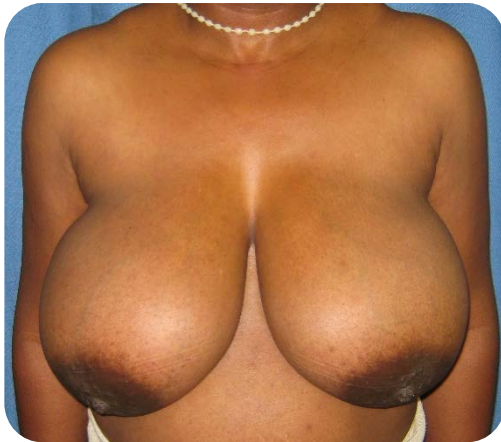- ✓ Setback : scarring, problems of the NAC (alteration in sensitivity + compromised circulation) but improvement on breast shape

- **Short scar procedures :**

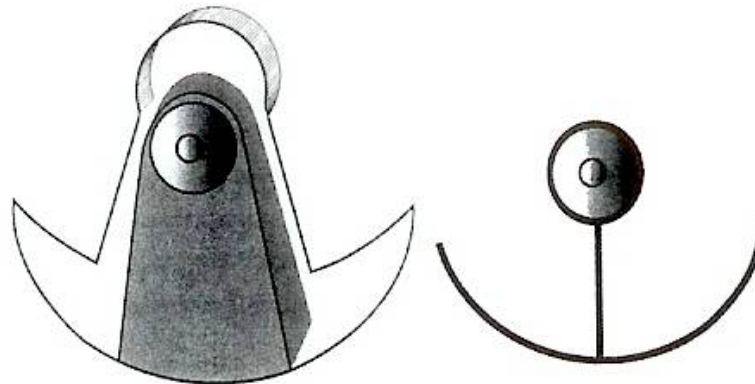
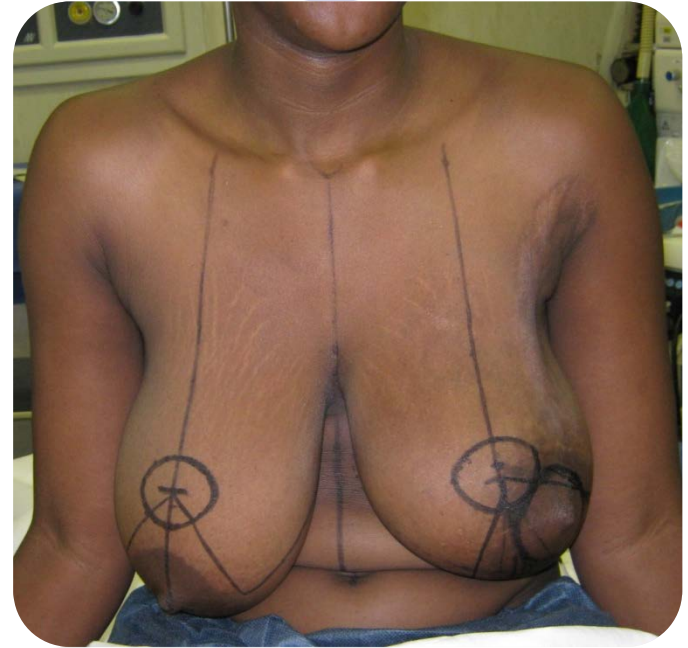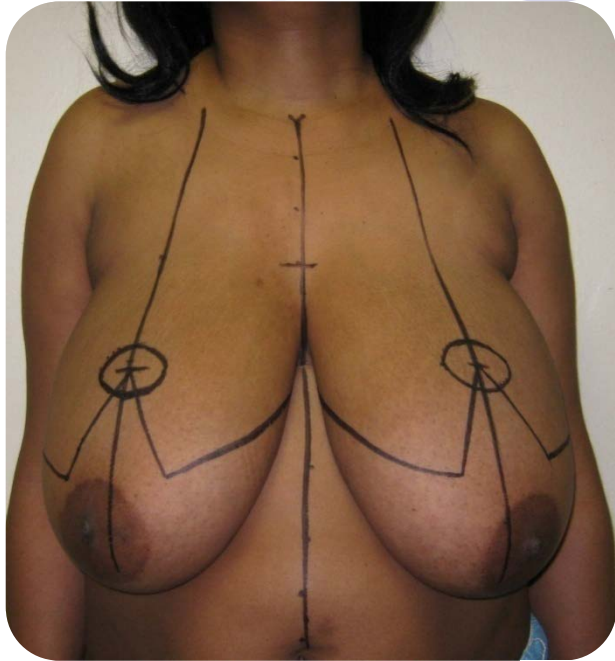
- ✓ Emphasis on breast shape (coning), decreased breast scarring, maintenance of NAC sensitivity & circulation

# Goals of breast reduction

- Volumetric reduction in breast size
- Preservation of breast function
- Achieving aesthetically pleasing breasts

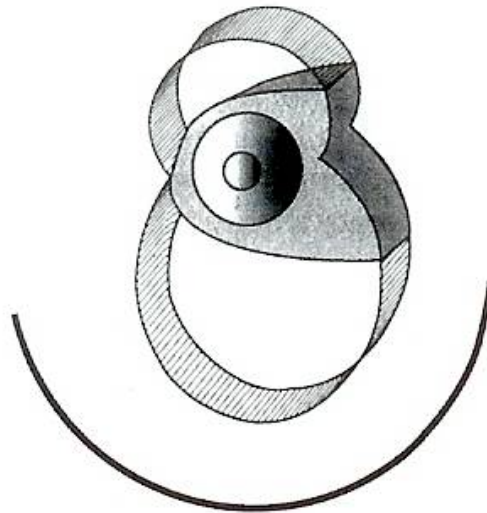
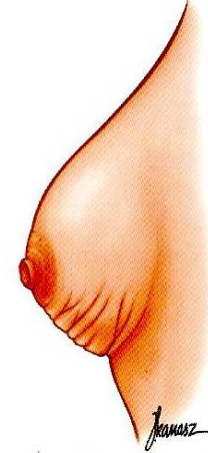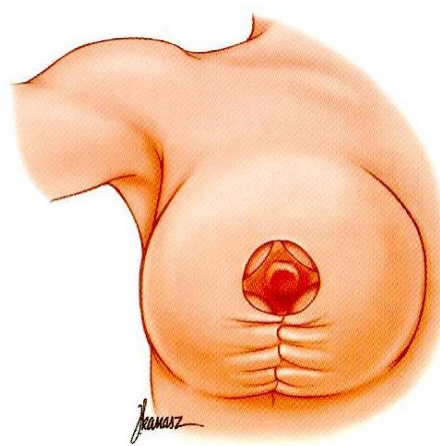
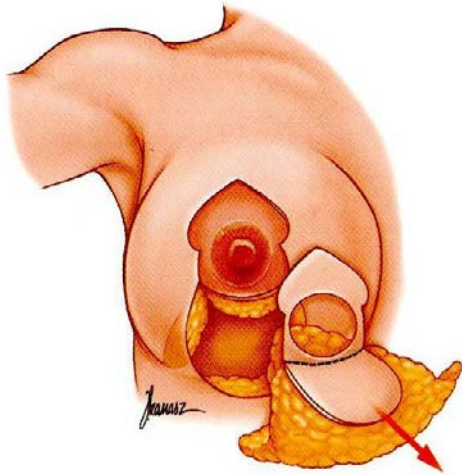


# Classification: Wise pattern





# Classification: Vertical pattern





# Survey : current trends RM

## ▪ **PRS Sept '99 :**

- ✓ Wise pattern – 74 %
- ✓ Popular vertical scar = Lejour – 12 %

## ▪ **PRS Dec 2004 :**

- ✓ Wise pattern – 44 %
- ✓ Popular vertical scar = Hall-Findlay

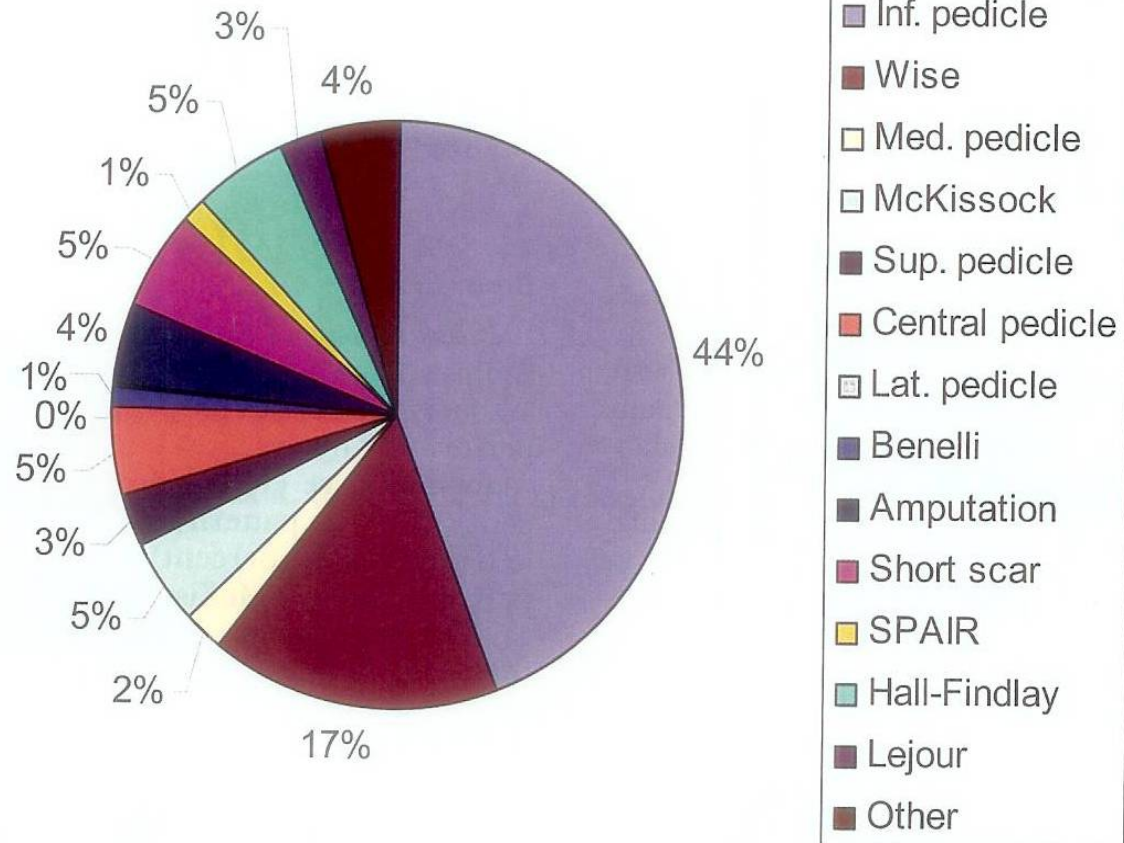
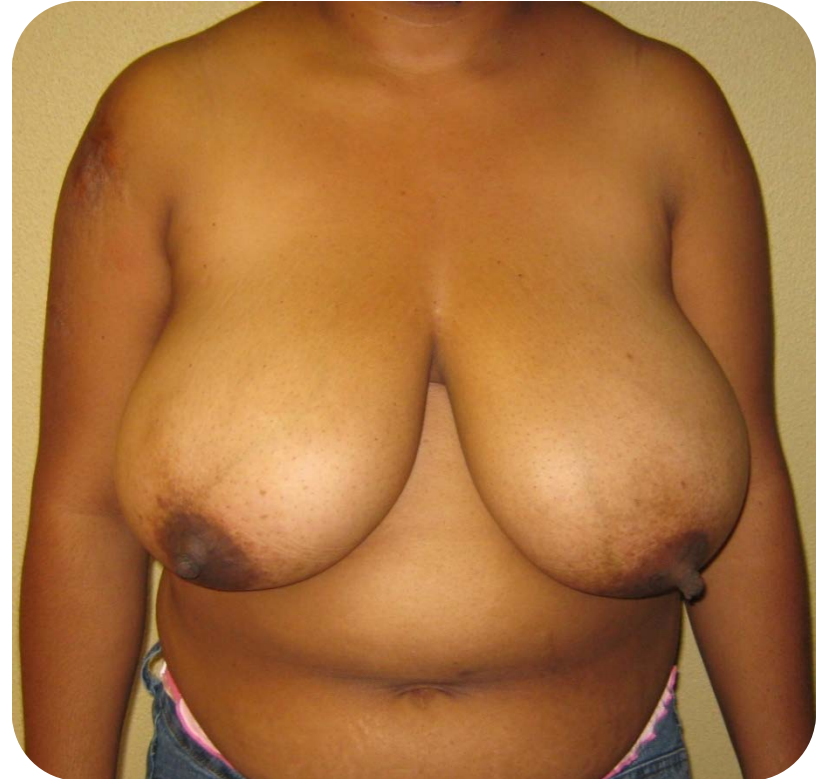
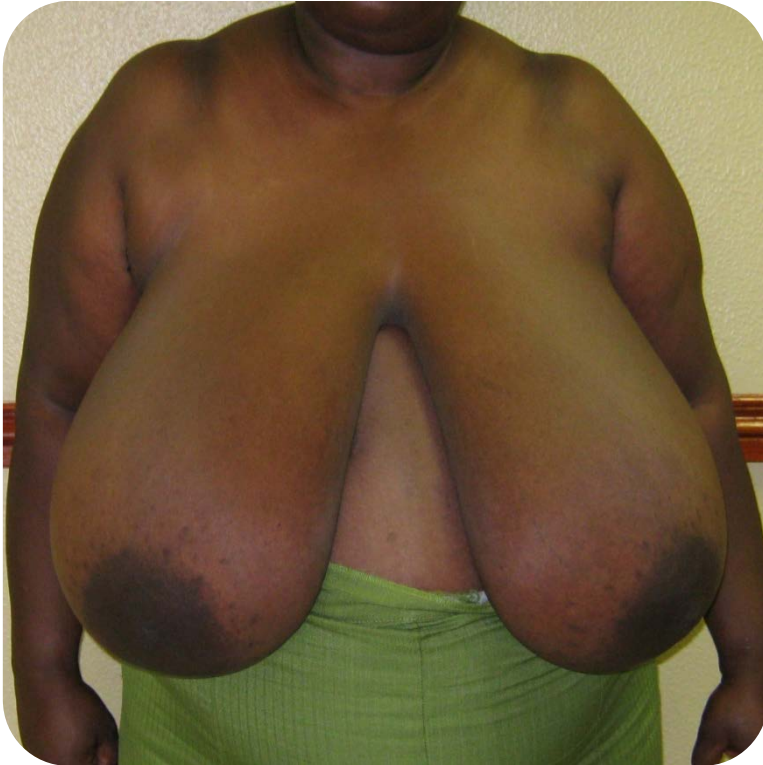


FIG. 1. Breast reduction techniques. SPAIR, short scar periareolar inferior pedicle reduction.

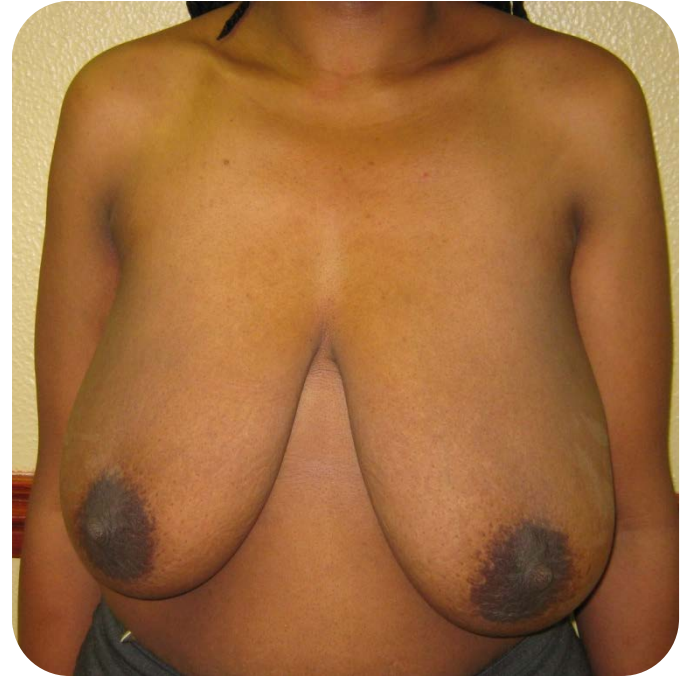
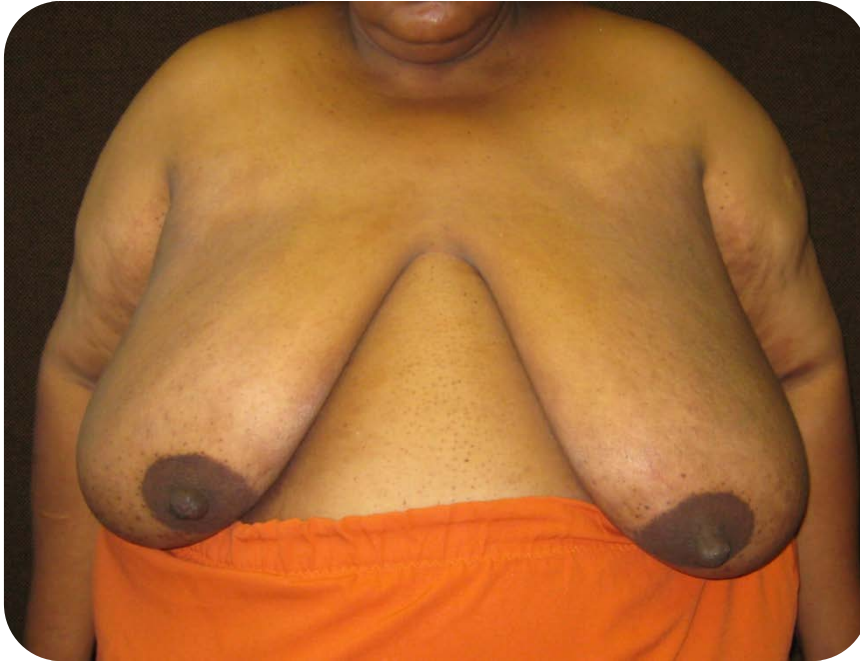



Why do patients need reduction  
mammaplasty ?

# Synmastia

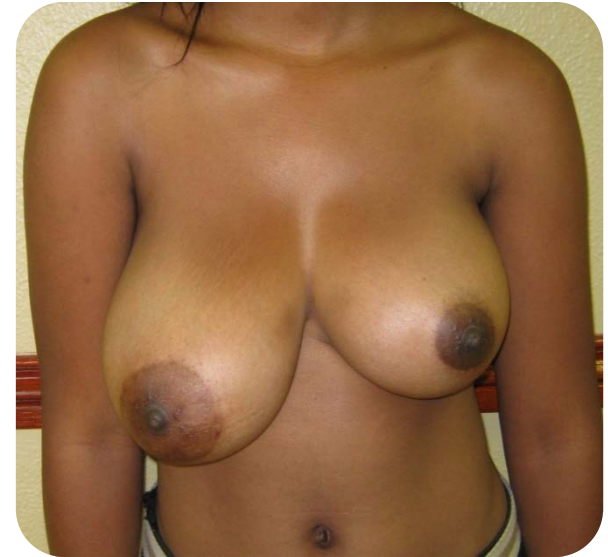
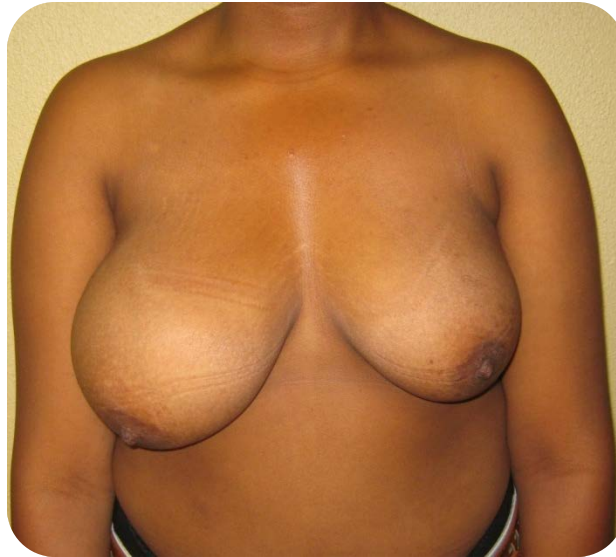
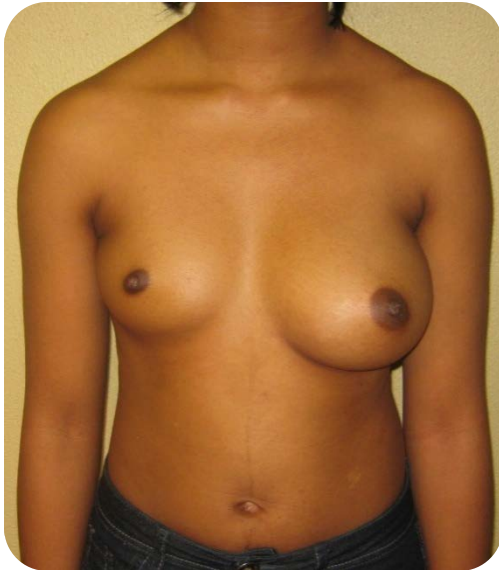


Large but empty

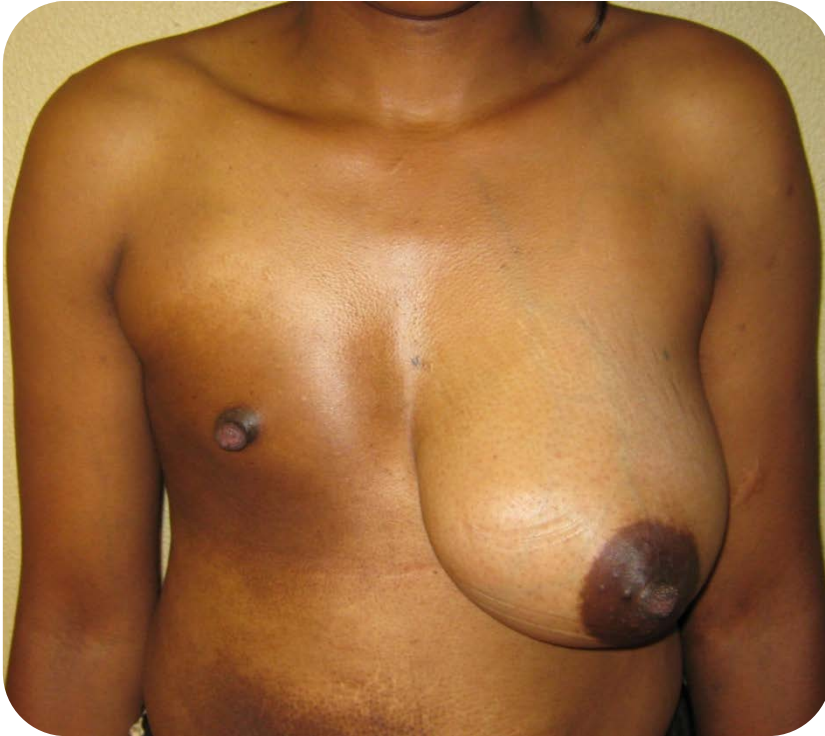



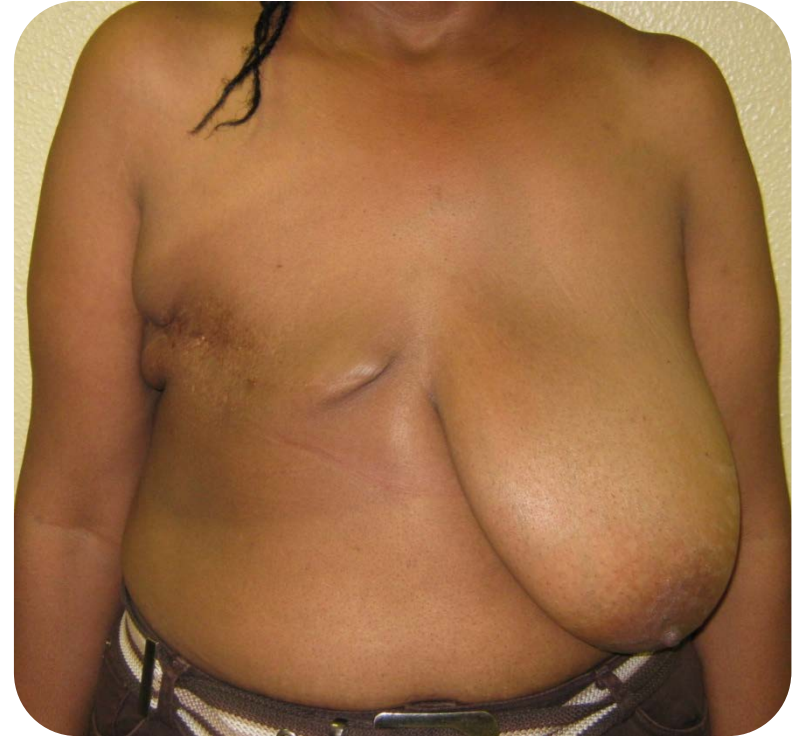# Asymmetry



# Contra-lateral breast absence



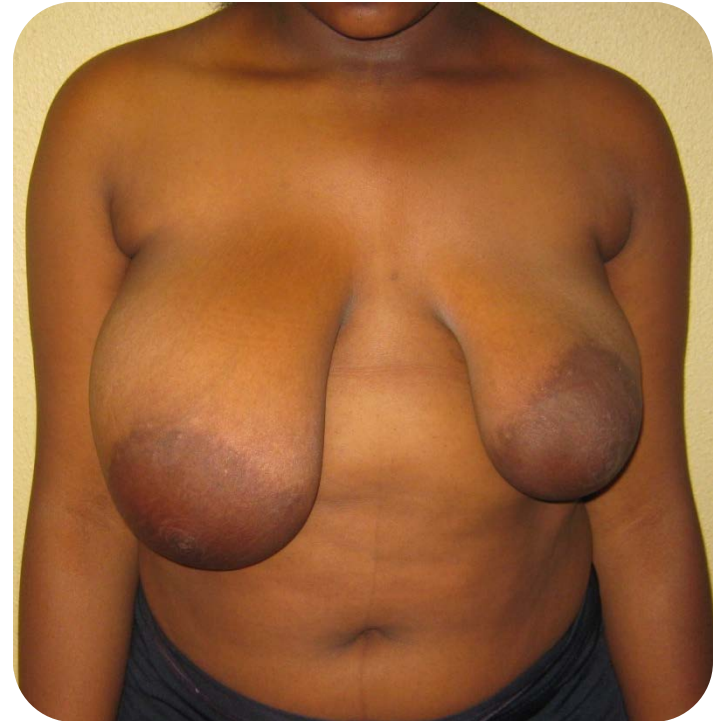
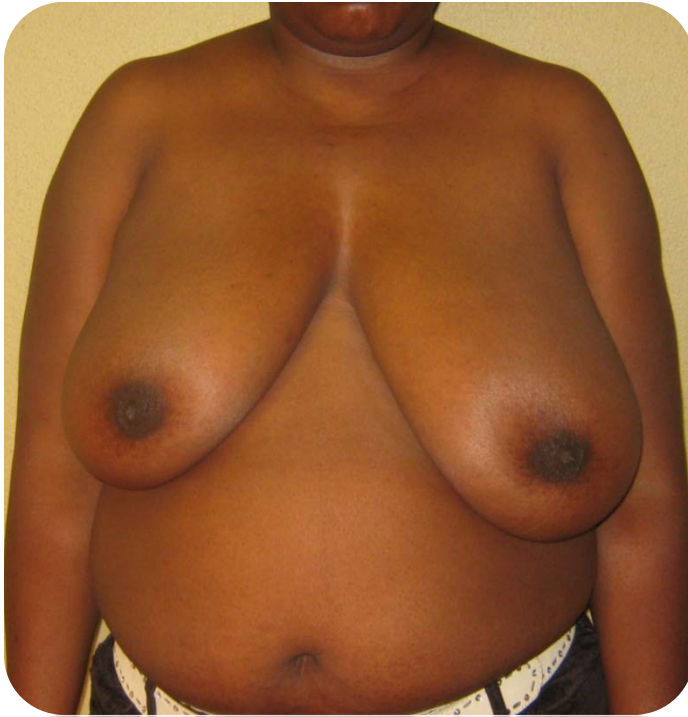

Congenital – Poland syndrome



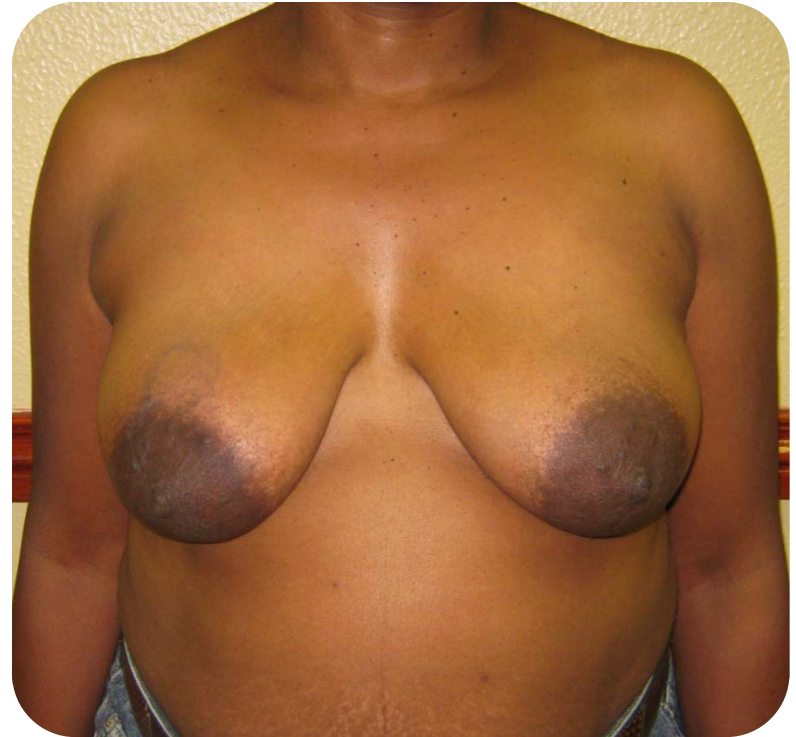
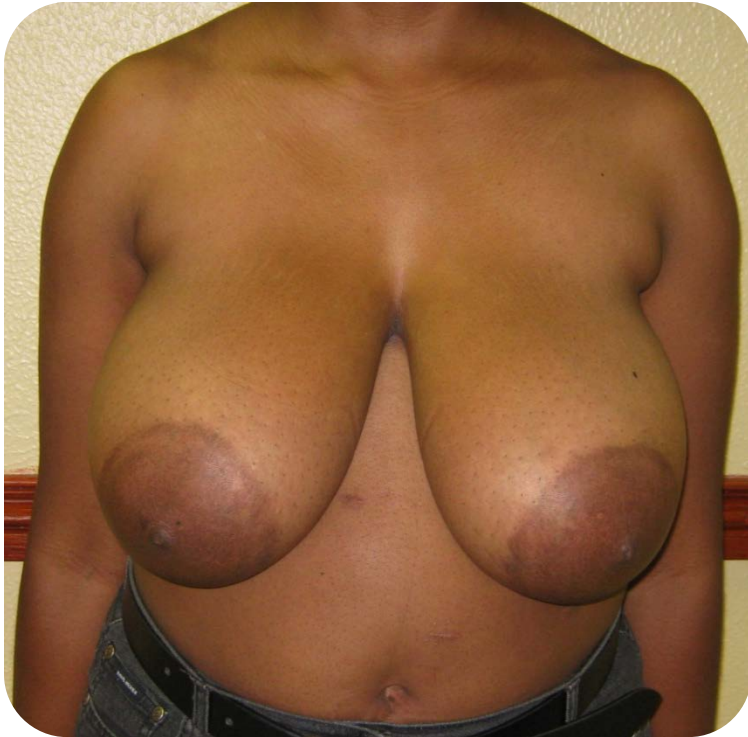

Acquired – Mastectomy



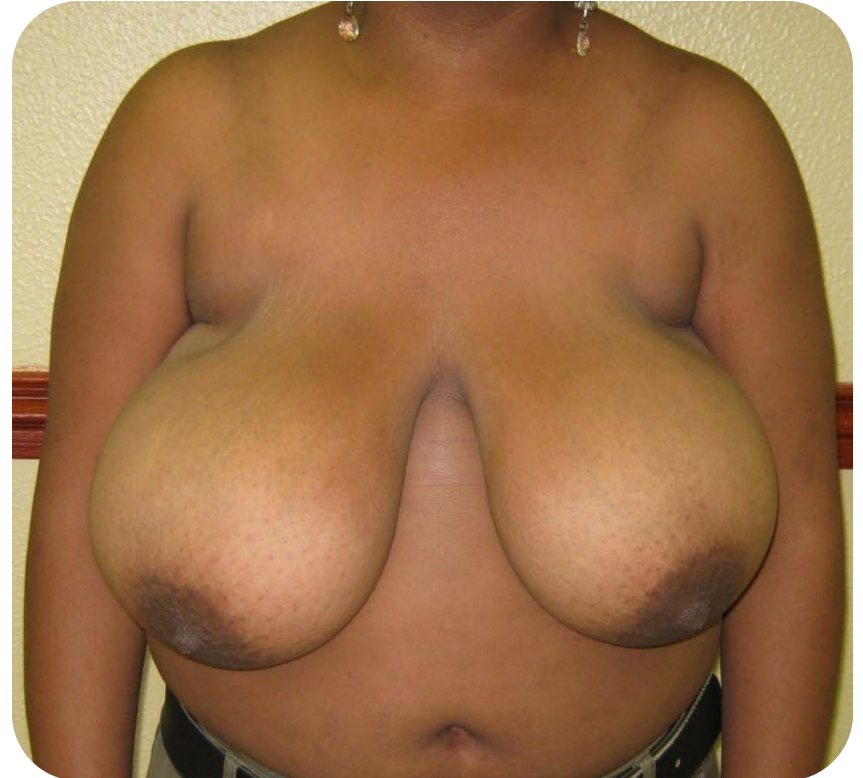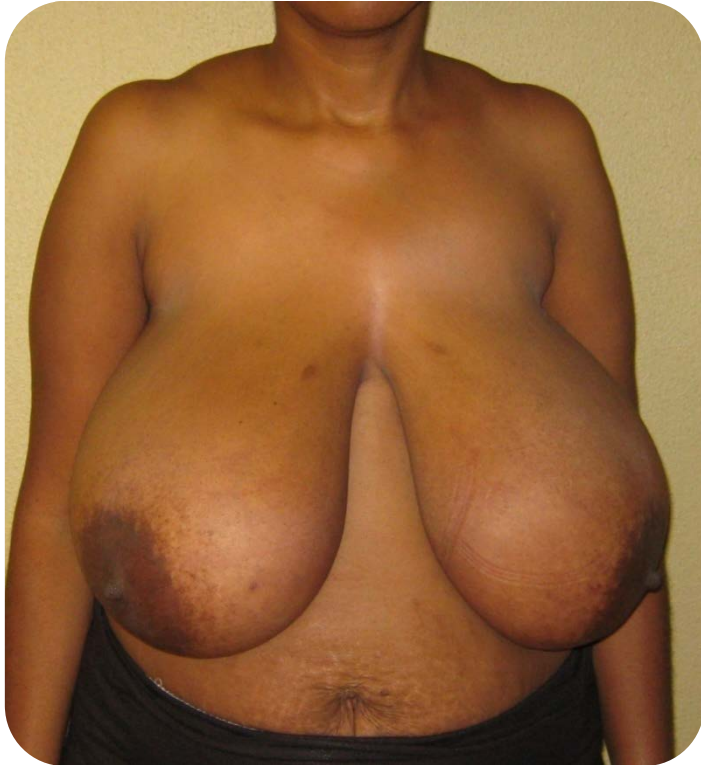# Tubular / Tuberous



Large areolar

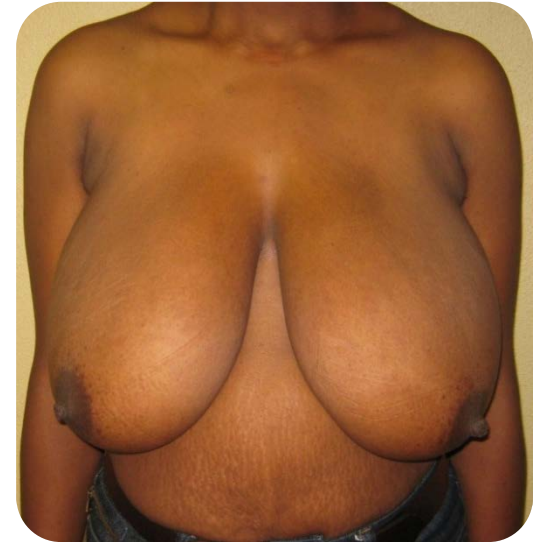
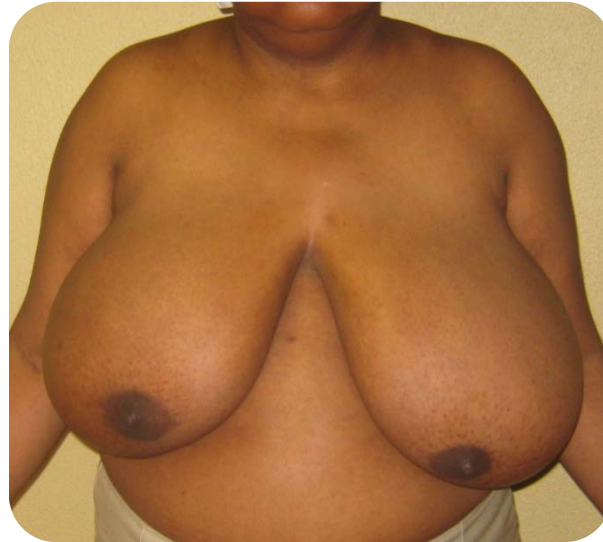
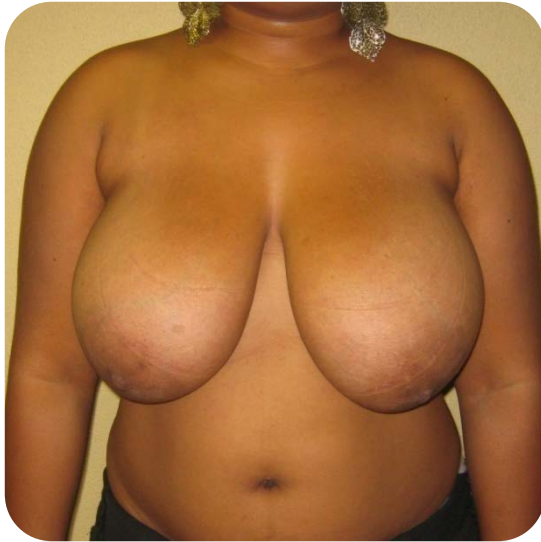



# Pedunculated breasts

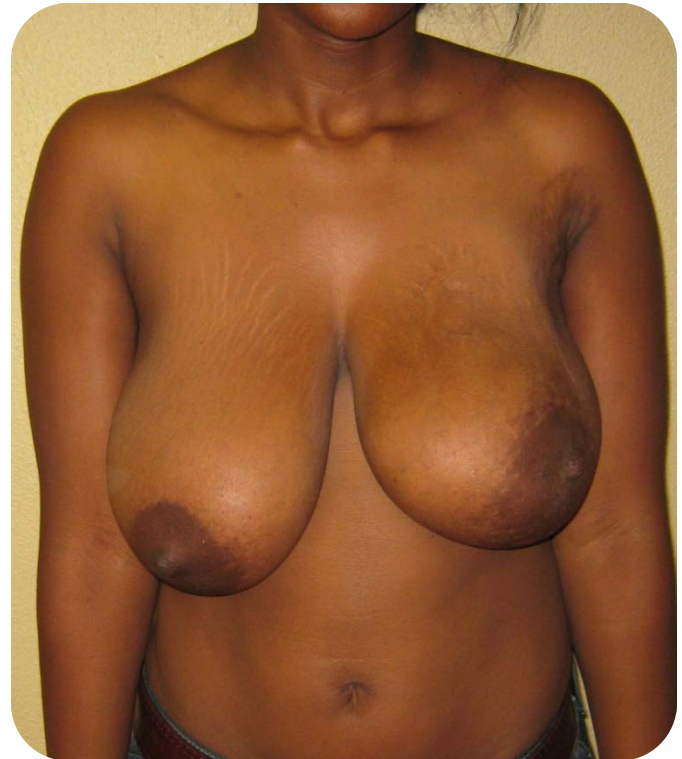
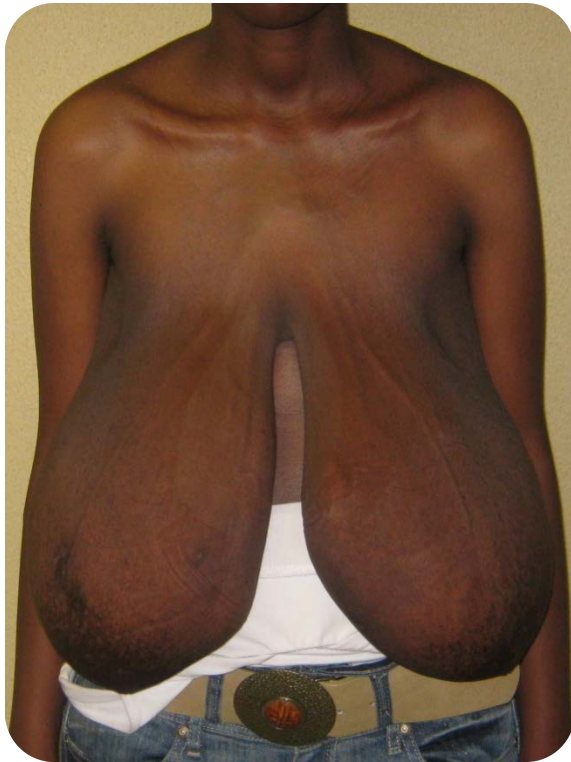




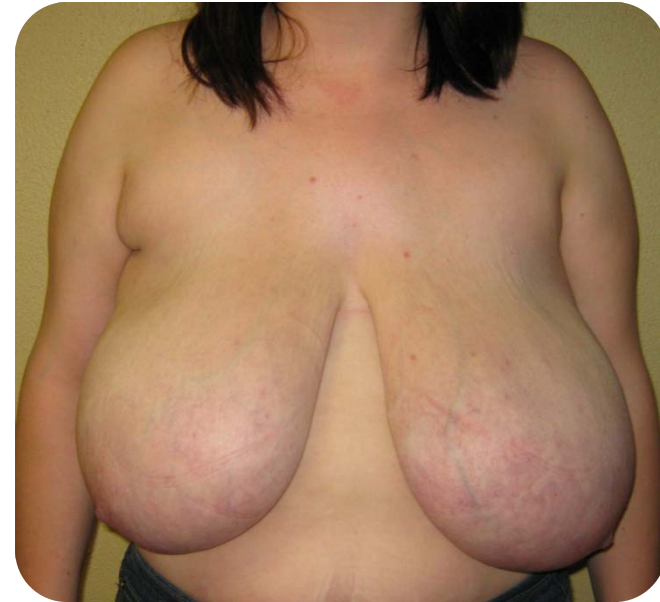
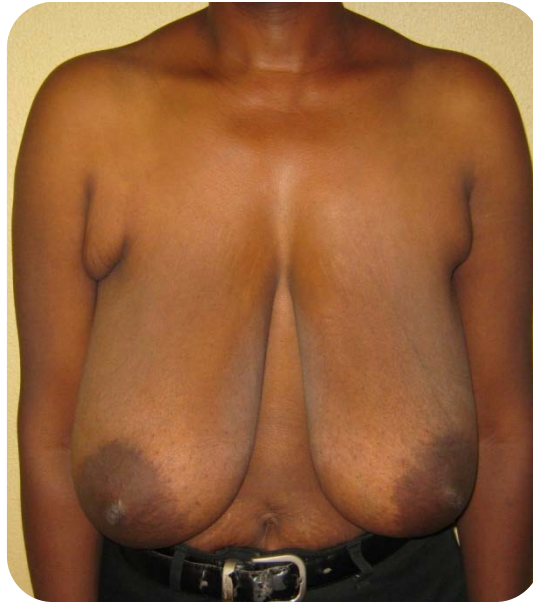
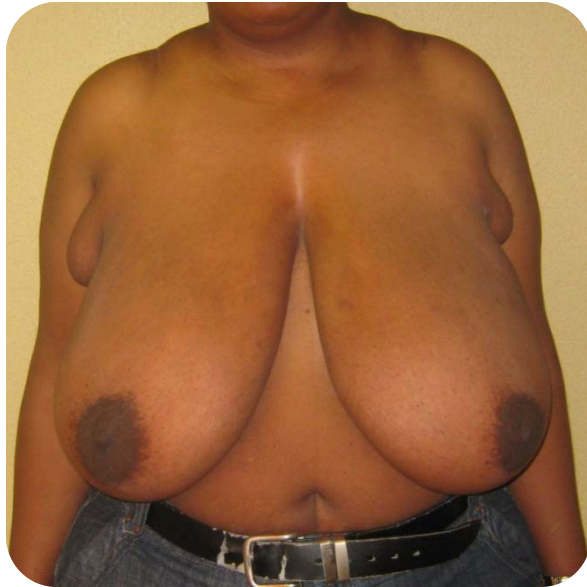
# Nipple anomalies



# Breast pathology



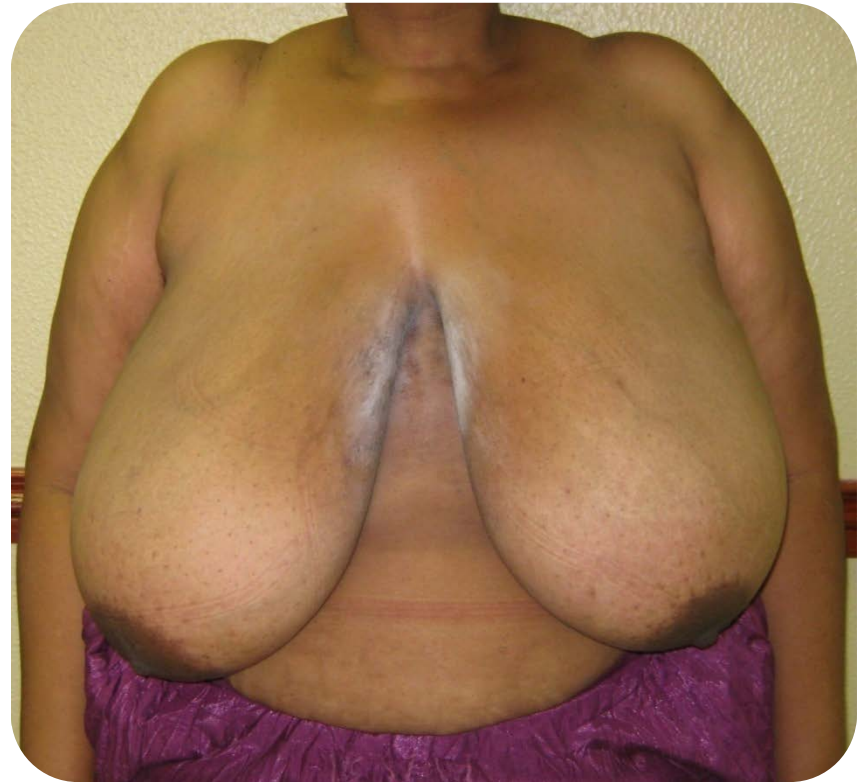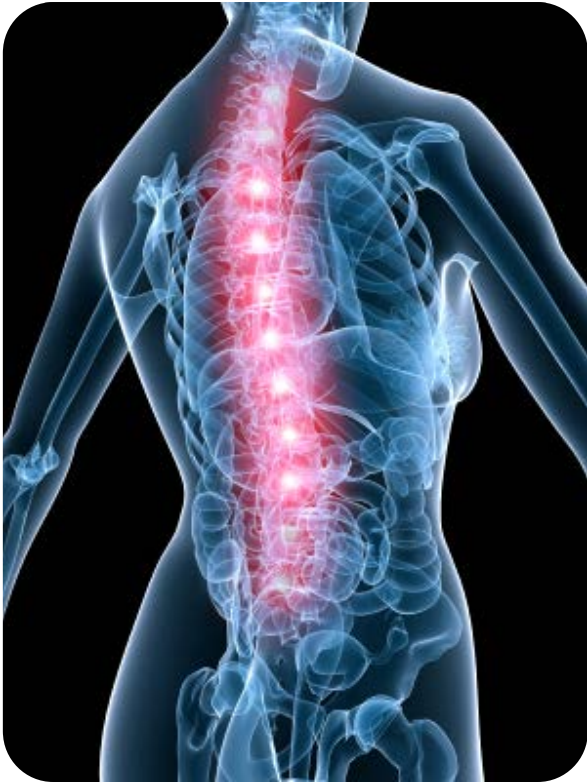# Accessory breasts



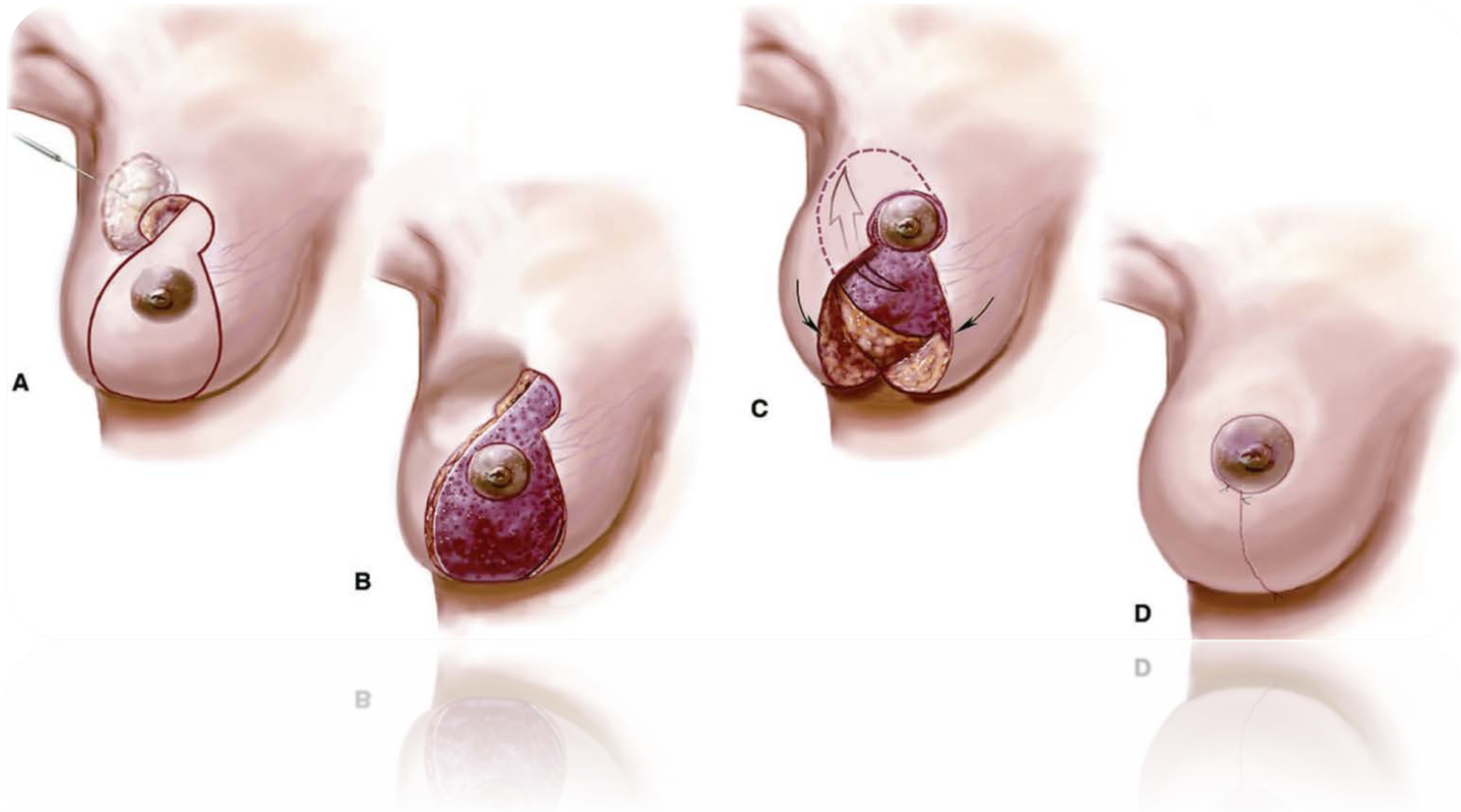




# Medical problems

Pains, backache, intertrigo, brazier strap marks/ furrow

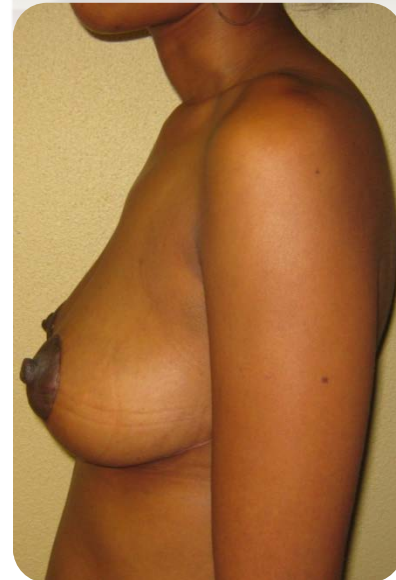
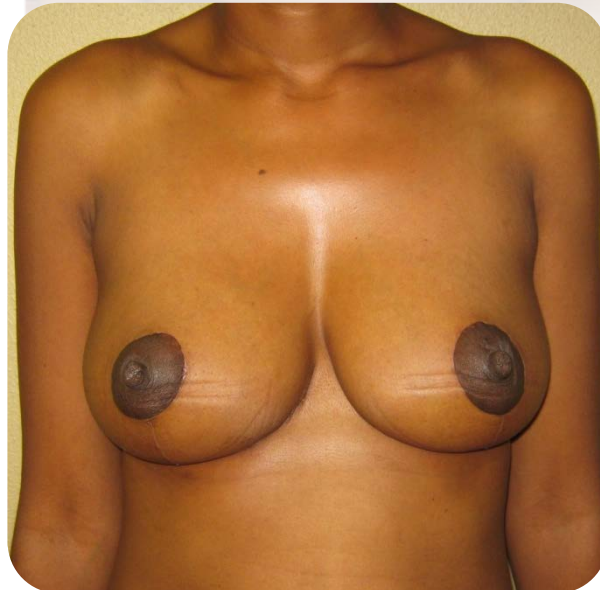
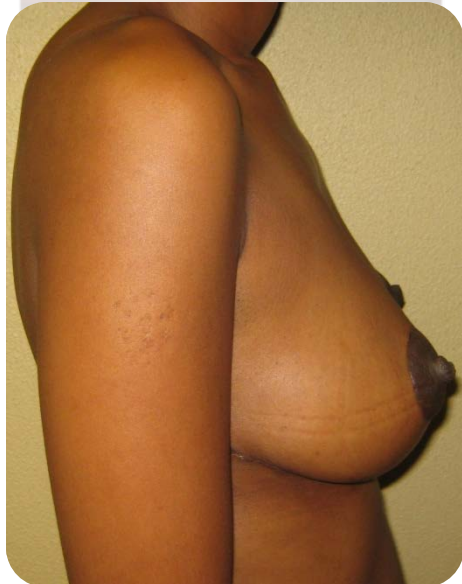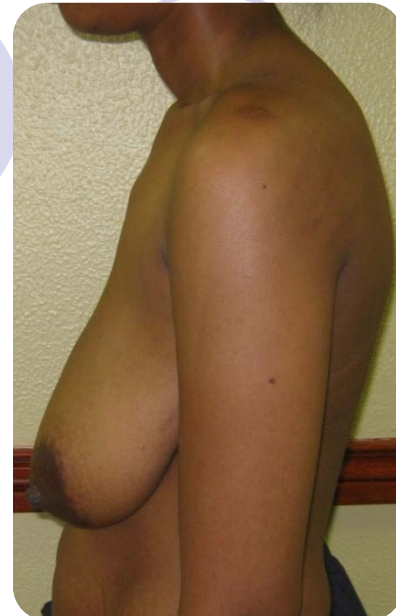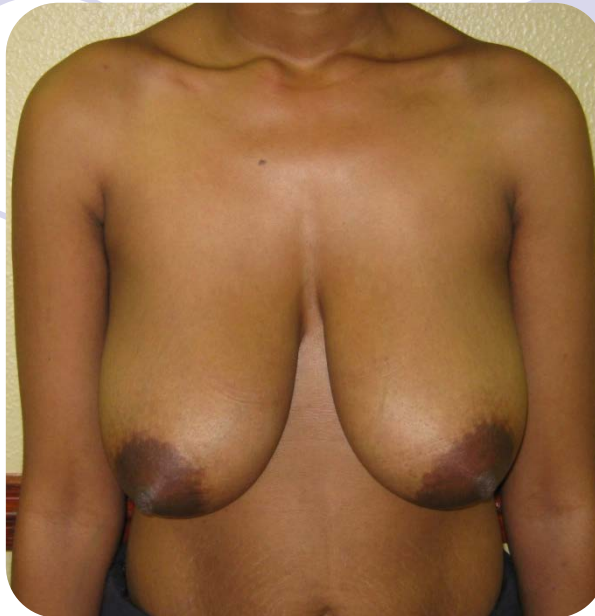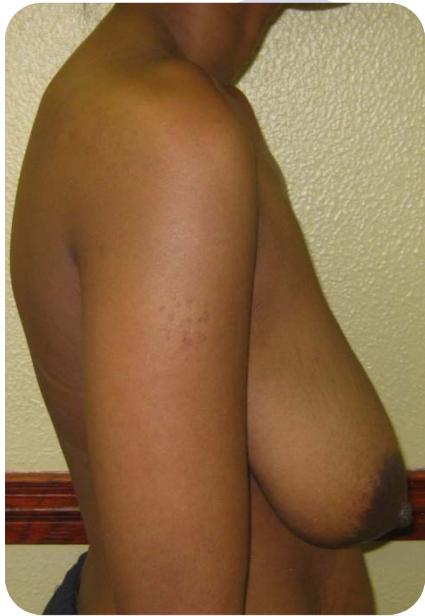# Oncoplastic surgery

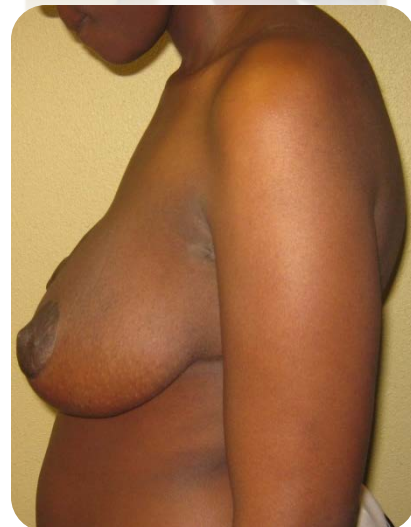
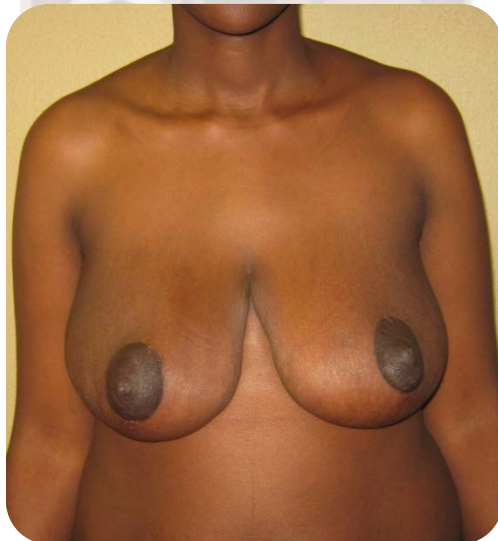
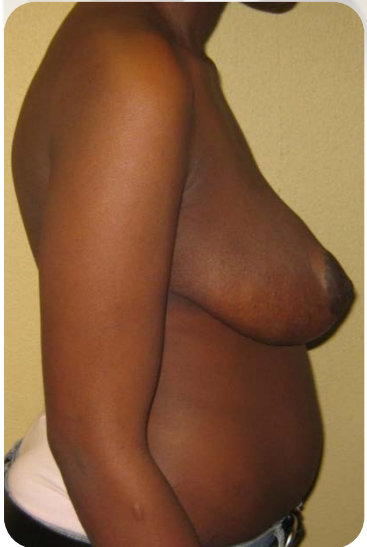
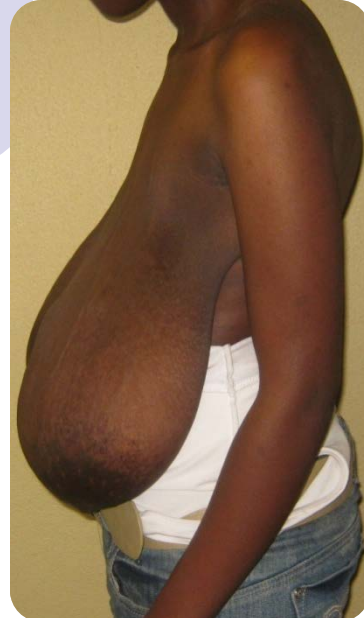
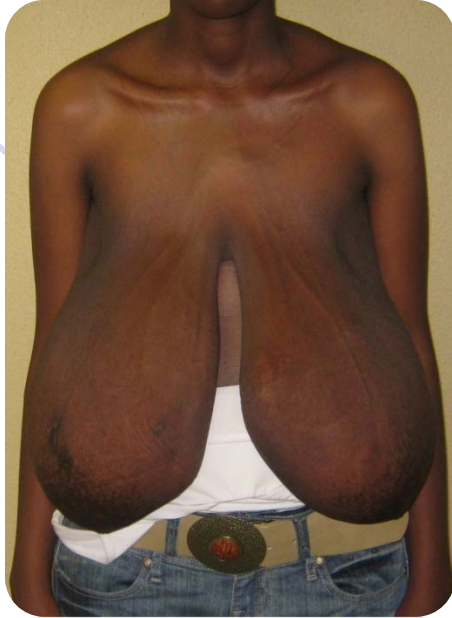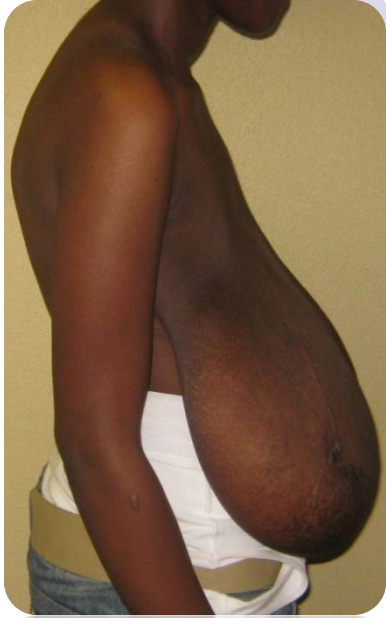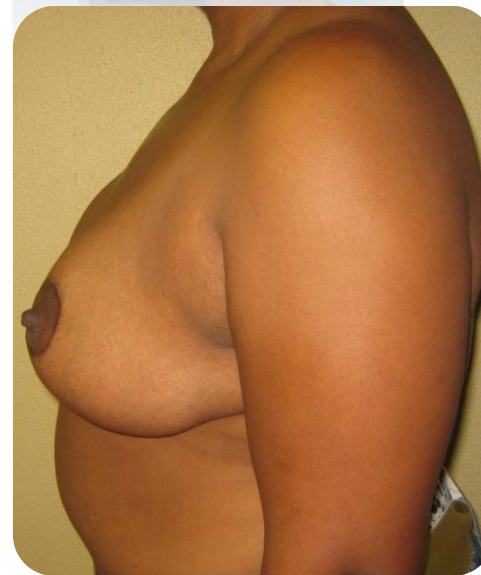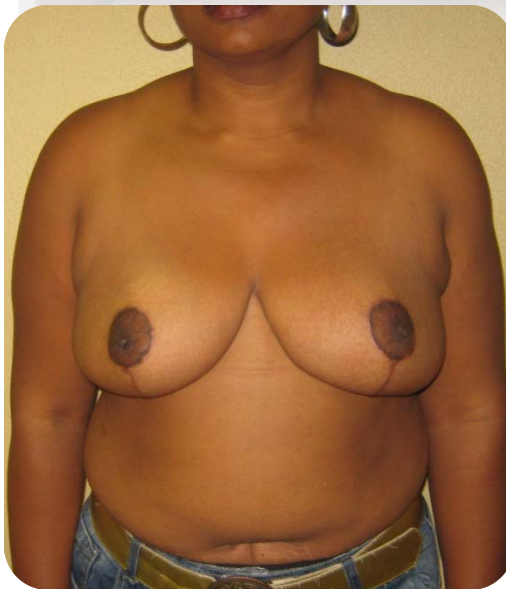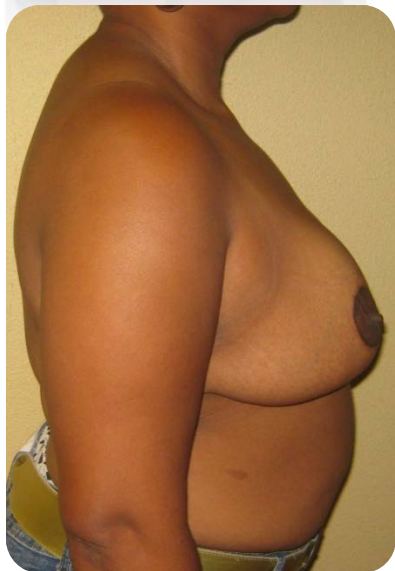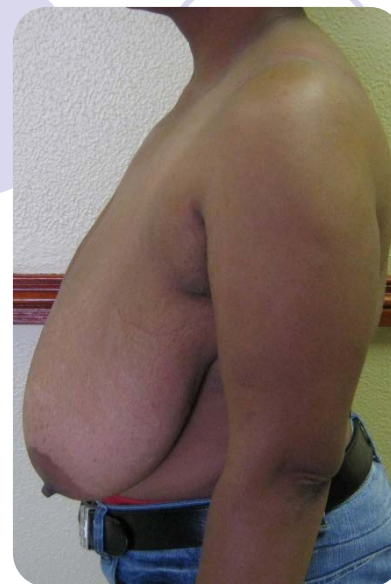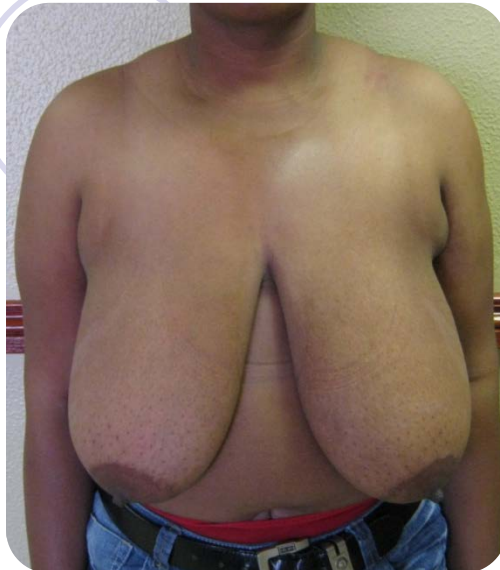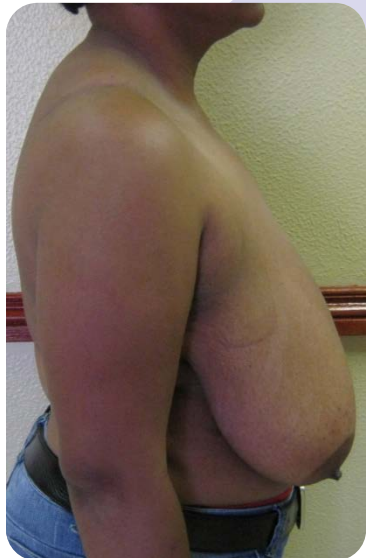Pre & Post operative results



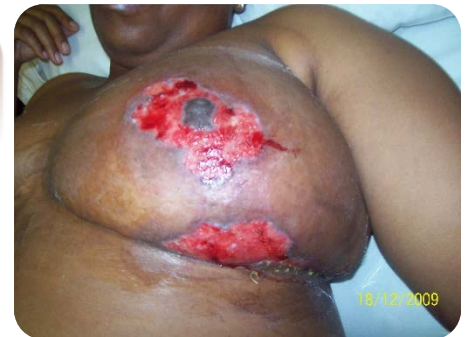
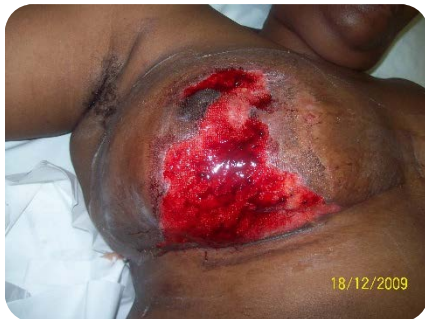
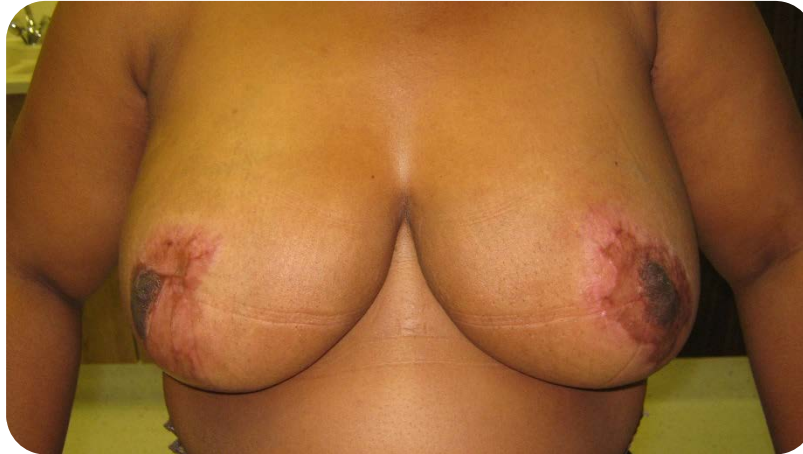
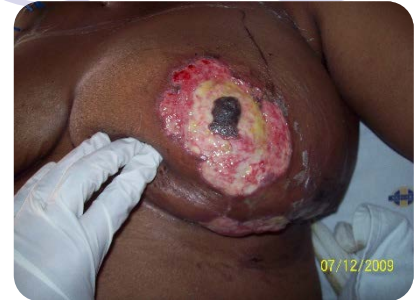
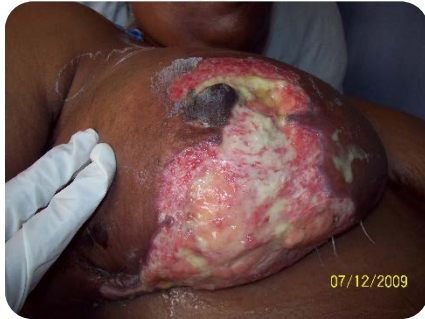



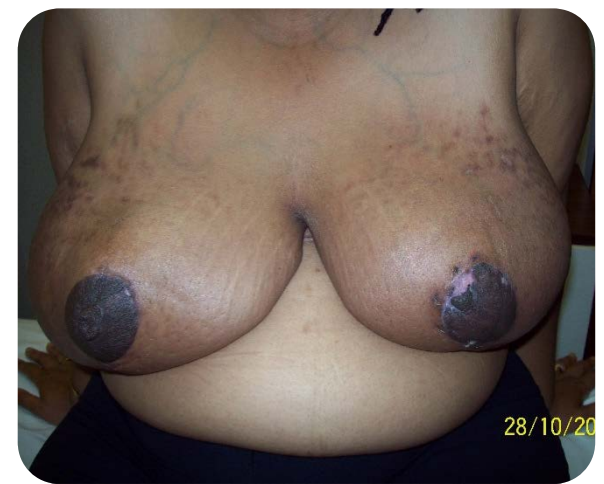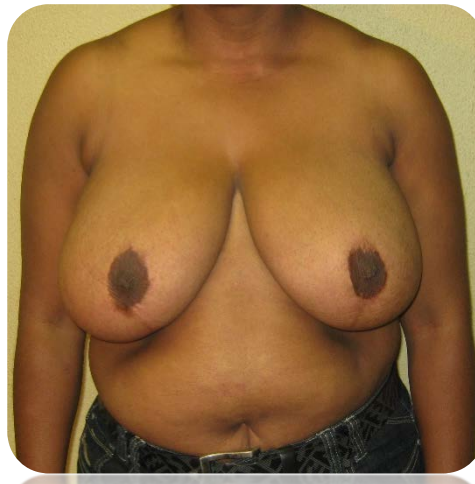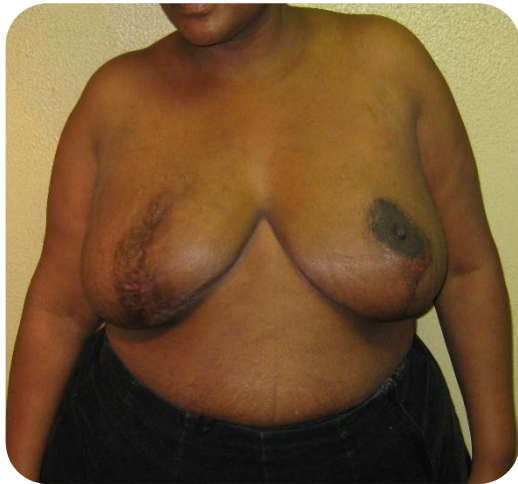# Complications:



# Complications:








28/10/20

# Controversies



- BBR - Adolescent girls / Pensioners
- BBR - Before or after completion of child birth / family
- Oncological breast surveillance for BBR pts:
  - ✓ Pre-op mammogram
  - ✓ Breast reduction specimen – routine histology analysis



# Thank You

